A 24-year-old man is evaluated for recurrent episodes of abdominal pain and bloody diarrhea. The patient has also had low-grade fevers and fatigue. Physical examination reveals left lower quadrant tenderness. CT scan of the abdomen shows thickening of the distal colon and rectum. During one of the laboratory tests, the patient's anticoagulated blood is placed in an upright, thin glass tube and left undisturbed. His red blood cells form a stack and settle to the bottom at a fast rate of 50 mm/hr. Serum levels of which of the following substances is most closely associated with this observed finding?

A. Bradykinin

B. Erythropoietin

C. Interleukin (IL)-6

D. Leukotriene B_4

E. Platelet-activating factor

F. Thromboxane A_2

Submit

A 24-year-old man is evaluated for recurrent episodes of abdominal pain and bloody diarrhea. The patient has also had low-grade fevers and fatigue. Physical examination reveals left lower quadrant tenderness. CT scan of the abdomen shows thickening of the distal colon and rectum. During one of the laboratory tests, the patient's anticoagulated blood is placed in an upright, thin glass tube and left undisturbed. His red blood cells form a stack and settle to the bottom at a fast rate of 50 mm/hr. Serum levels of which of the following substances is most closely associated with this observed finding?

- A. Bradykinin (3%)
- B. Erythropoietin (7%)
- ✓ C. Interleukin (IL)-6 (45%)
- D. Leukotriene B_4 (4%)
- E. Platelet-activating factor (13%)
- F. Thromboxane A_2 (25%)

Omitted
Correct answer
C

45%
Answered correctly

03 secs
Time Spent

03/30/2020
Last Updated

Explanation

This patient who has recurrent abdominal pain and bloody diarrhea with CT evidence of bowel wall thickening in the distal colon and rectum likely has ulcerative colitis. Chronic inflammatory conditions are characterized by the persistent stimulation of neutrophils and macrophages, leading to long-term elevation of circulating pro-inflammatory cytokines such as IL-1, **IL-6**, tumor necrosis factor-alpha, and interferon-gamma. The liver

This patient who has recurrent abdominal pain and bloody diarrhea with CT evidence of bowel wall thickening in the distal colon and rectum likely has ulcerative colitis. Chronic inflammatory conditions are characterized by the persistent stimulation of neutrophils and macrophages, leading to long-term elevation of circulating pro-inflammatory cytokines such as IL-1, **IL-6**, tumor necrosis factor-alpha, and interferon-gamma. The liver responds to these circulating cytokines (particularly IL-6) by generating **acute phase reactants**, proteins that modulate and influence the inflammatory response and play some role in innate immunity.

Testing for acute phase reactants can help diagnose and track conditions associated with inflammation, including infections, autoimmune diseases, and malignancies. The test described in this case is the **erythrocyte sedimentation rate** (ESR), which begins by placing whole blood in a narrow vertical tube. Erythrocytes settle at the bottom of the tube over time due to gravity as their density is greater than plasma. ESR is a measure of the length of plasma on top of the erythrocyte sediment layer at 1 hour. The presence of acute phase reactants, particularly fibrinogen and globulins, causes erythrocytes to overcome their zeta potential (negative charge that separates them) and form a stacked, **rouleaux formation**, which settles to the bottom of the tube more quickly and **increases ESR**.

(Choice A) Bradykinin is a component of the kinin system. It is a short-lived peptide that causes vasodilation, increases vascular permeability, stimulates endothelial smooth muscle dilation, and mediates pain.

(Choice B) Erythropoietin is a growth factor for erythrocyte precursors in the bone marrow. It is produced by peritubular cells of the kidneys in response to hypoxia.

(Choice D) Leukotriene B_4 is a metabolite of arachidonic acid. Its main function is to stimulate neutrophil migration to the site of inflammation.

(Choice E) Platelet-activating factor is released by endothelium, platelets, and immune cells, and is involved in leukocyte function (eg, endothelium attachment, phagocytosis, degranulation), platelet stimulation, and changes to vascular tone and permeability.

(Choice F) Thromboxane A_2 is one of the products of the cyclooxygenase pathway. It is synthesized by platelets and causes platelet activation and aggregation. It does not cause erythrocyte aggregation or rouleaux formation.

Educational objective:
Chronic inflammation is associated with increased circulating pro-inflammatory cytokines (eg, IL-1, IL-6, tumor necrosis factor-alpha), which stimulates the liver to release acute-phase reactants (eg, C-reactive protein, fibrinogen). The presence of acute-phase reactants increases the erythrocyte sedimentation rate, a nonspecific marker for inflammation.

in a narrow vertical tube. Erythrocytes settle at the bottom of the tube over time due to gravity as their density is greater than plasma. ESR is a measure of the length of plasma on top of the erythrocyte sediment layer at 1 hour. The presence of acute phase reactants, particularly fibrinogen and globulins, causes erythrocytes to overcome their zeta potential (negative charge that separates them) and form a stacked, **rouleaux formation**, which settles to the bottom of the tube more quickly and **increases ESR**.

(Choice A) Bradykinin is a component of the kinin system. It is a short-lived peptide that causes vasodilation, increases vascular permeability, stimulates endothelial smooth muscle dilation, and mediates pain.

(Choice B) Erythropoietin is a growth factor for erythrocyte precursors in the bone marrow. It is produced by peritubular cells of the kidneys in response to hypoxia.

(Choice D) Leukotriene B_4 is a metabolite of arachidonic acid. Its main function is to stimulate neutrophil migration to the site of inflammation.

(Choice E) Platelet-activating factor is released by endothelium, platelets, and immune cells, and is involved in leukocyte function (eg, endothelium attachment, phagocytosis, degranulation), platelet stimulation, and changes to vascular tone and permeability.

(Choice F) Thromboxane A_2 is one of the products of the cyclooxygenase pathway. It is synthesized by platelets and causes platelet activation and aggregation. It does not cause erythrocyte aggregation or rouleaux formation.

Educational objective:
Chronic inflammation is associated with increased circulating pro-inflammatory cytokines (eg, IL-1, IL-6, tumor necrosis factor-alpha), which stimulates the liver to release acute-phase reactants (eg, C-reactive protein, fibrinogen). The presence of acute-phase reactants increases the erythrocyte sedimentation rate, a nonspecific marker for inflammation.

References

- Acute-phase proteins and other systemic responses to inflammation.

Pathology	General Principles	Inflammatory bowel disease
Subject	System	Topic

Copyright © UWorld. All rights reserved.

Settings

1
2
3
4
5
6
7
8
9
10
11

Item 2 of 11
Question Id: 1753

Mark | Previous | Next | Full Screen | Tutorial | Lab Values | Notes | Calculator | Reverse Color | Text Zoom | Settings

A 27-year-old woman comes to the office for a health maintenance examination. The patient has no chronic medical conditions and no family history of cancer. She has had several sexual partners and takes oral contraceptives for birth control. Vital signs are normal. Physical examination, including pelvic examination, is normal. A Pap test is performed and reveals a squamous intraepithelial lesion that tests positive for human papillomavirus. A cervical biopsy is performed and reveals low-grade dysplasia. Which of the following features distinguishes this patient's lesion from cervical malignancy?

- A. Abundant mitoses
- B. Disordered maturation
- C. Loss of cell polarity
- D. Nuclear abnormalities
- E. Pleomorphism
- F. Reversibility of changes

Submit

Block Time Remaining: 00:00:03
TUTOR

3 | Feedback | Suspend | End Block

A 27-year-old woman comes to the office for a health maintenance examination. The patient has no chronic medical conditions and no family history of cancer. She has had several sexual partners and takes oral contraceptives for birth control. Vital signs are normal. Physical examination, including pelvic examination, is normal. A Pap test is performed and reveals a squamous intraepithelial lesion that tests positive for human papillomavirus. A cervical biopsy is performed and reveals low-grade dysplasia. Which of the following features distinguishes this patient's lesion from cervical malignancy?

- A. Abundant mitoses (2%)
- B. Disordered maturation (2%)
- C. Loss of cell polarity (3%)
- D. Nuclear abnormalities (2%)
- E. Pleomorphism (3%)
- ✓ F. Reversibility of changes (85%)

Omitted
Correct answer
F

85%
Answered correctly

01 sec
Time Spent

04/19/2020
Last Updated

Explanation

HPV infection & progression to cervical cancer

Normal cervix Cervical intraepithelial lesion (neoplasia) Cervical carcinoma

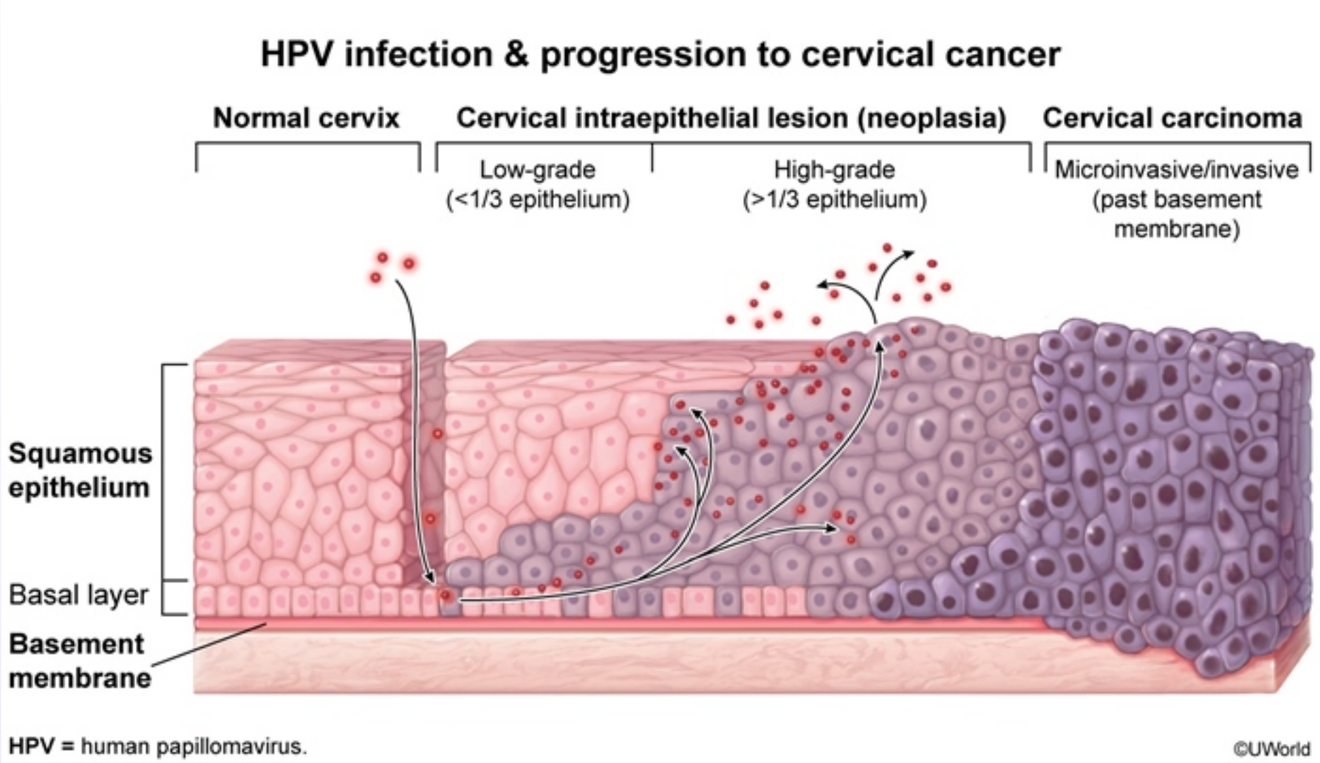

Squamous dysplasia is marked by a breakdown in the normal organized progression from tall cells in the basal layer to flattened cells on the surface. Individual cells are often pleomorphic (differing in shape and size) and also show significant abnormalities such as abundant mitotic figures and large hyperchromatic nuclei. The risk of progression to invasive carcinoma is directly linked to the degree of epithelial architecture disruption, as follows:

- **Low-grade dysplasia** – involves only a small portion of the epithelium (typically less than one-third); it usually **spontaneously regresses** and requires no treatment.

Squamous dysplasia is marked by a breakdown in the normal organized progression from tall cells in the basal layer to flattened cells on the surface. Individual cells are often pleomorphic (differing in shape and size) and also show significant abnormalities such as abundant mitotic figures and large hyperchromatic nuclei. The risk of progression to invasive carcinoma is directly linked to the degree of epithelial architecture disruption, as follows:

- **Low-grade dysplasia** – involves only a small portion of the epithelium (typically less than one-third); it usually **spontaneously regresses** and requires no treatment.

- **High-grade dysplasia** – involves most or all of the epithelium but does not penetrate the basement membrane; it is associated with a **high risk of progression** to invasive cancer and is typically referred to as carcinoma in situ.

- **Invasive carcinoma** – involves the full thickness of the epithelium and **penetrates the basement membrane**. The malignant cells may be similar to those found in the tissue of origin (well differentiated), or may lack the characteristic features of cells found in the tissue of origin (poorly differentiated).

Cervical dysplasia is almost always due to underlying infection with oncogenic serotypes of human papilloma virus (HPV). In infected cells, viral proteins (eg, E6, E7) bind to tumor-suppressing host proteins (eg, p53) and result in their destruction by the proteasome. This eliminates a crucial check on cellular growth and can lead to dysplasia.

(Choices A, B, C, D, and E) Abundant mitoses, disordered maturation, changes in cell polarity, nuclear abnormalities, and pleomorphism can be seen in both dysplasia and invasive carcinoma.

Educational objective:
Dysplasia is characterized by disruption of organized epithelial cell differentiation with marked cellular pleomorphism. Although high-grade dysplasia (involving most or the entire epithelial layer) often progresses to invasive cancer, low-grade dysplasia (involving a small portion of epithelium) typically spontaneously regresses. Invasive cancer occurs when the abnormal cells penetrate the basement membrane.

Pathology	Miscellaneous (Multisystem)	Cervical cancer
Subject	System	Topic

Settings

1
2
3
4
5
6
7
8
9
10
11

Item 2 of 11
Question Id: 1753

Mark | Previous | Next | Full Screen | Tutorial | Lab Values | Notes | Calculator | Reverse Color | Text Zoom | Settings

Exhibit Display

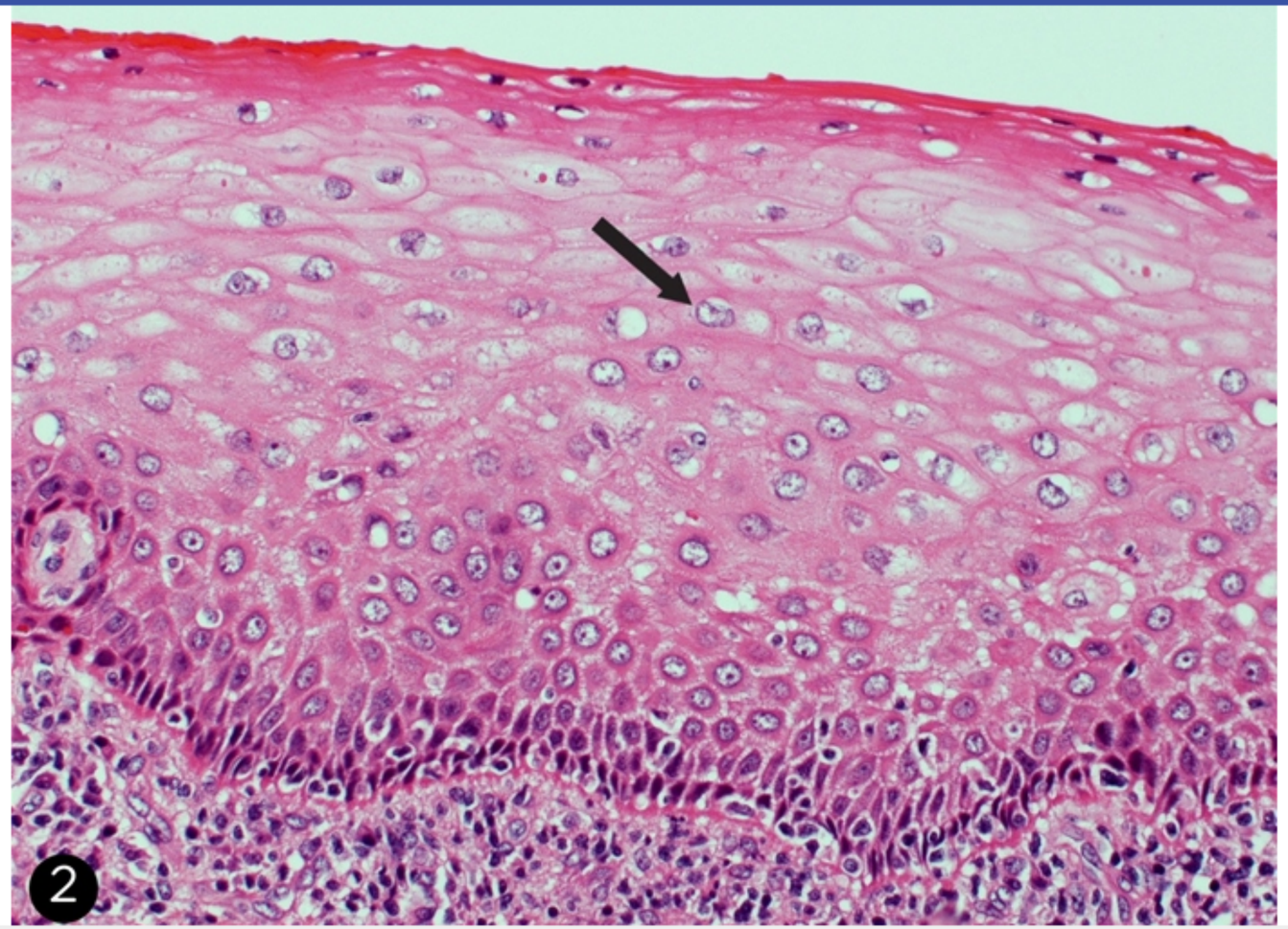

Zoom In | Zoom Out | Reset | Add To New Card | Existing Card

Block Time Remaining: 00:00:04
TUTOR

3 | Feedback | Suspend | End Block

Settings

- 1
- 2
- 3
- 4
- 5
- 6
- 7
- 8
- 9
- 10
- 11

Item 2 of 11
Question Id: 1753

Mark | Previous | Next | Full Screen | Tutorial | Lab Values | Notes | Calculator | Reverse Color | Text Zoom | Settings

Exhibit Display

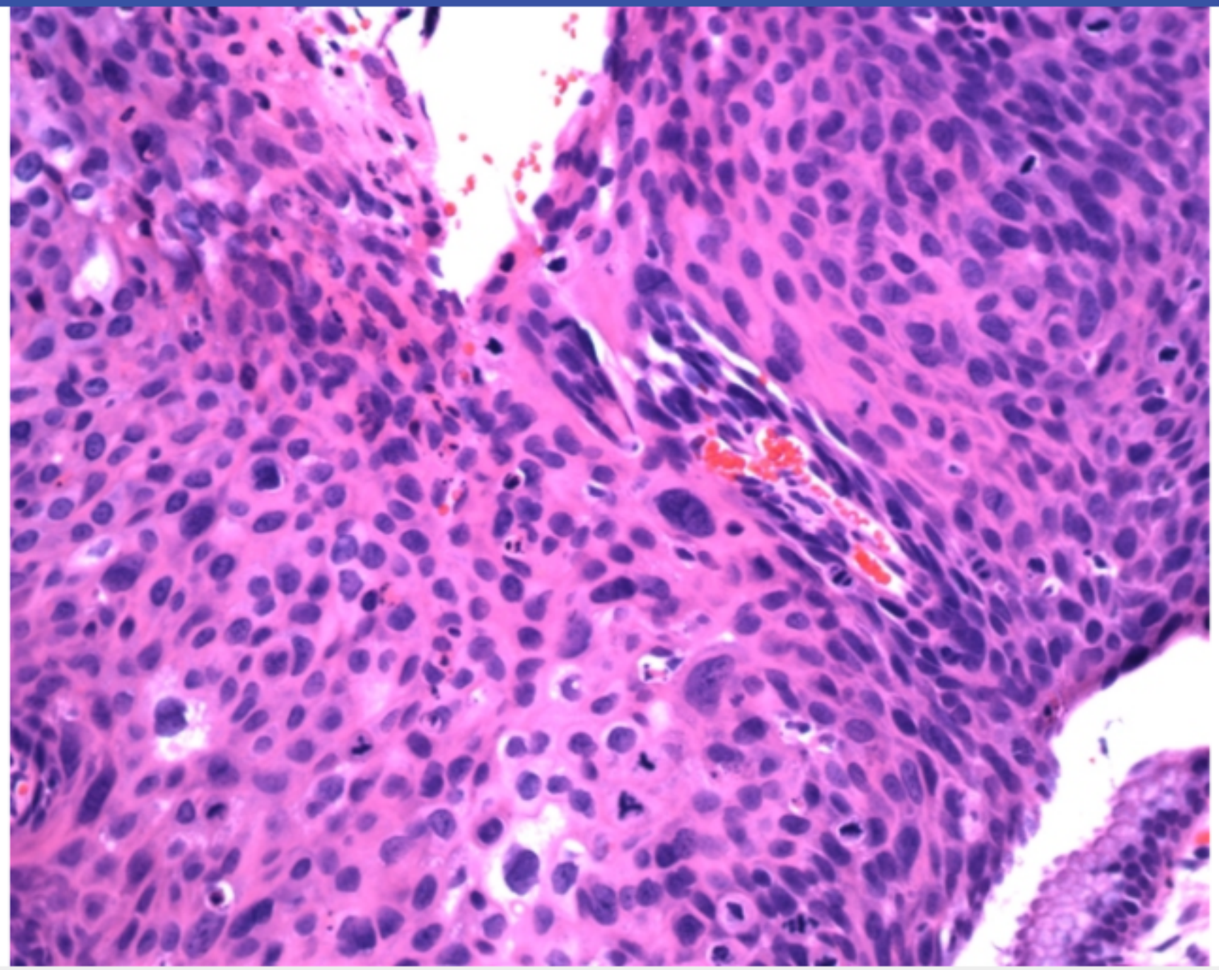

Zoom In | Zoom Out | Reset | Add To New Card | Existing Card

Block Time Remaining: 00:00:04
TUTOR

3 | Feedback | Suspend | End Block

surface. Individual cells are often pleomorphic (differing in shape and size) and also show significant abnormalities such as abundant mitotic figures and large hyperchromatic nuclei. The risk of progression to invasive carcinoma is directly linked to the degree of epithelial architecture disruption, as follows:

- **Low-grade dysplasia** – involves only a small portion of the epithelium (typically less than one-third); it usually **spontaneously regresses** and requires no treatment.

- **High-grade dysplasia** – involves most or all of the epithelium but does not penetrate the basement membrane; it is associated with a **high risk of progression** to invasive cancer and is typically referred to as carcinoma in situ.

- **Invasive carcinoma** – involves the full thickness of the epithelium and **penetrates the basement membrane**. The malignant cells may be similar to those found in the tissue of origin (well differentiated), or may lack the characteristic features of cells found in the tissue of origin (poorly differentiated).

Cervical dysplasia is almost always due to underlying infection with oncogenic serotypes of human papilloma virus (HPV). In infected cells, viral proteins (eg, E6, E7) bind to tumor-suppressing host proteins (eg, p53) and result in their destruction by the proteasome. This eliminates a crucial check on cellular growth and can lead to dysplasia.

(Choices A, B, C, D, and E) Abundant mitoses, disordered maturation, changes in cell polarity, nuclear abnormalities, and pleomorphism can be seen in both dysplasia and invasive carcinoma.

Educational objective:
Dysplasia is characterized by disruption of organized epithelial cell differentiation with marked cellular pleomorphism. Although high-grade dysplasia (involving most or the entire epithelial layer) often progresses to invasive cancer, low-grade dysplasia (involving a small portion of epithelium) typically spontaneously regresses. Invasive cancer occurs when the abnormal cells penetrate the basement membrane.

Pathology	Miscellaneous (Multisystem)	Cervical cancer
Subject	System	Topic

Copyright © UWorld. All rights reserved.

Settings

1
2
3
4
5
6
7
8
9
10
11

Item 3 of 11
Question Id: 19080

Mark | Previous | Next | Full Screen | Tutorial | Lab Values | Notes | Calculator | Reverse Color | Text Zoom | Settings

A 35-year-old, previously healthy man is evaluated immediately after accidental exposure to ionizing radiation at a fluoroscopy manufacturing facility. The patient is currently asymptomatic. Vital signs are normal. Physical examination shows no abnormalities. If radiation exposure is significant, which of the following cells are most likely to be affected first?

- A. Bladder epithelial cells
- B. Cardiac myocytes
- C. Intestinal crypt cells
- D. Renal proximal tubular cells
- E. Skeletal muscle cells
- F. Type II pneumocytes

Submit

Block Time Remaining: 00:00:04
TUTOR

0 | Feedback | Suspend | End Block

A 35-year-old, previously healthy man is evaluated immediately after accidental exposure to ionizing radiation at a fluoroscopy manufacturing facility. The patient is currently asymptomatic. Vital signs are normal. Physical examination shows no abnormalities. If radiation exposure is significant, which of the following cells are most likely to be affected first?

A. Bladder epithelial cells (25%)
B. Cardiac myocytes (3%)
✓ C. Intestinal crypt cells (49%)
D. Renal proximal tubular cells (9%)
E. Skeletal muscle cells (1%)
F. Type II pneumocytes (9%)

Omitted
Correct answer
C

49%
Answered correctly

01 sec
Time Spent

05/16/2020
Last Updated

Explanation

Exposure to **ionizing radiation** causes cell injury directly through **DNA double-strand breakage** and indirectly through the generation of **free radicals** that can damage DNA and other cellular components. Significant DNA damage results in the **upregulation of p53**, which inhibits replication and induces **apoptosis** of the affected cell.

The effects of ionizing radiation vary based on the rate of cellular division. **Highly proliferative cells** (eg, stem cells) have less time to repair radiation induced DNA damage before cell death occurs. Therefore, these cells are highly sensitive to ionizing radiation and most likely to be

Exposure to **ionizing radiation** causes cell injury directly through **DNA double-strand breakage** and indirectly through the generation of **free radicals** that can damage DNA and other cellular components. Significant DNA damage results in the **upregulation of p53**, which inhibits replication and induces **apoptosis** of the affected cell.

The effects of ionizing radiation vary based on the rate of cellular division. **Highly proliferative cells** (eg, stem cells) have less time to repair radiation-induced DNA damage before cell death occurs. Therefore, these cells are highly sensitive to ionizing radiation and most likely to be **affected first** following exposure.

Intestinal crypt stem cells divide continuously to produce new intestinal epithelial cells, which have a short life span and are completely renewed every 3-5 days. Rapid denudation of the gastrointestinal mucosa can occur if the radiation dose is significant, resulting in nausea/vomiting, diarrhea, and gastrointestinal bleeding.

Other cells that are highly sensitive to the effects of ionizing radiation include the following:

- Bone marrow: **hematopoietic progenitors** (pancytopenia)
- Gonads: spermatogonia (infertility)
- Skin: basal keratinocytes, hair follicle stem cells (desquamation, hair loss)

(Choices A and D) Bladder epithelial cells and renal proximal tubular epithelial cells have a much slower turnover rate (eg, weeks to months) compared with intestinal epithelial cells and are less likely to be affected first by exposure to ionizing radiation.

(Choices B and E) Cardiac and skeletal myocytes are long-lived, differentiated cells that do not rapidly divide and can more effectively repair radiation-induced DNA damage before cell death occurs.

(Choice F) Although type II pneumocytes can dedifferentiate and proliferate in response to injury to replace type I pneumocytes, they have a low rate of proliferation at rest and are less likely to be affected acutely by exposure to ionizing radiation.

Educational objective:
Ionizing radiation induces DNA damage (eg, double-strand breakage, free radical generation) that predominantly affects highly proliferative cells (eg, skin stem cells, hematogenous progenitors, intestinal crypt cells). These rapidly dividing cells are the first to be lost following significant

affected first following exposure.

Intestinal crypt stem cells divide continuously to produce new intestinal epithelial cells, which have a short life span and are completely renewed every 3-5 days. Rapid denudation of the gastrointestinal mucosa can occur if the radiation dose is significant, resulting in nausea/vomiting, diarrhea, and gastrointestinal bleeding.

Other cells that are highly sensitive to the effects of ionizing radiation include the following:

- Bone marrow: **hematopoietic progenitors** (pancytopenia)
- Gonads: spermatogonia (infertility)
- Skin: basal keratinocytes, hair follicle stem cells (desquamation, hair loss)

(Choices A and D) Bladder epithelial cells and renal proximal tubular epithelial cells have a much slower turnover rate (eg, weeks to months) compared with intestinal epithelial cells and are less likely to be affected first by exposure to ionizing radiation.

(Choices B and E) Cardiac and skeletal myocytes are long-lived, differentiated cells that do not rapidly divide and can more effectively repair radiation-induced DNA damage before cell death occurs.

(Choice F) Although type II pneumocytes can dedifferentiate and proliferate in response to injury to replace type I pneumocytes, they have a low rate of proliferation at rest and are less likely to be affected acutely by exposure to ionizing radiation.

Educational objective:
Ionizing radiation induces DNA damage (eg, double-strand breakage, free radical generation) that predominantly affects highly proliferative cells (eg, skin stem cells, hematogenous progenitors, intestinal crypt cells). These rapidly dividing cells are the first to be lost following significant radiation exposure, resulting in hair loss, pancytopenia, diarrhea, and nausea/vomiting.

Pathology	Poisoning & Environmental Exposure	Radiation injury
Subject	System	Topic

Copyright © UWorld. All rights reserved.

A 53-year-old man comes to the emergency department due to a few weeks of severe heartburn and difficulty swallowing. He has had mild to moderate heartburn for several years and has tried weight loss, elevating the head of the bed while sleeping, and several months of proton pump inhibitor therapy. Other medical problems include hypertension and hypothyroidism. Temperature is 36.7 C (98.1 F), blood pressure is 130/80 mm Hg, pulse is 78/min, and respirations are 16/min. BMI is 25 kg/m^2. Physical examination is unremarkable. An upper gastrointestinal endoscopy is performed, and esophageal biopsy shows columnar epithelium with interspersed goblet cells. A similar adaptive response can be seen in which of the following scenarios?

A. Bronchial epithelial cells in a chronic cigarette smoker

B. Epidermal cells in a patient with psoriasis

C. Melanocytes in a large, irregular mole

D. Myocardial cells in a patient with aortic stenosis

E. Skeletal myocytes after prolonged immobility

Submit

A 53-year-old man comes to the emergency department due to a few weeks of severe heartburn and difficulty swallowing. He has had mild to moderate heartburn for several years and has tried weight loss, elevating the head of the bed while sleeping, and several months of proton pump inhibitor therapy. Other medical problems include hypertension and hypothyroidism. Temperature is 36.7 C (98.1 F), blood pressure is 130/80 mm Hg, pulse is 78/min, and respirations are 16/min. BMI is 25 kg/m^2. Physical examination is unremarkable. An upper gastrointestinal endoscopy is performed, and esophageal biopsy shows columnar epithelium with interspersed goblet cells. A similar adaptive response can be seen in which of the following scenarios?

- ✓ A. Bronchial epithelial cells in a chronic cigarette smoker (96%)
- B. Epidermal cells in a patient with psoriasis (1%)
- C. Melanocytes in a large, irregular mole (1%)
- D. Myocardial cells in a patient with aortic stenosis (0%)
- E. Skeletal myocytes after prolonged immobility (0%)

Omitted
Correct answer
A

96%
Answered correctly

01 sec
Time Spent

05/07/2020
Last Updated

Explanation

Squamous metaplasia

Normal respiratory epithelium | Metaplasia | Dysplasia

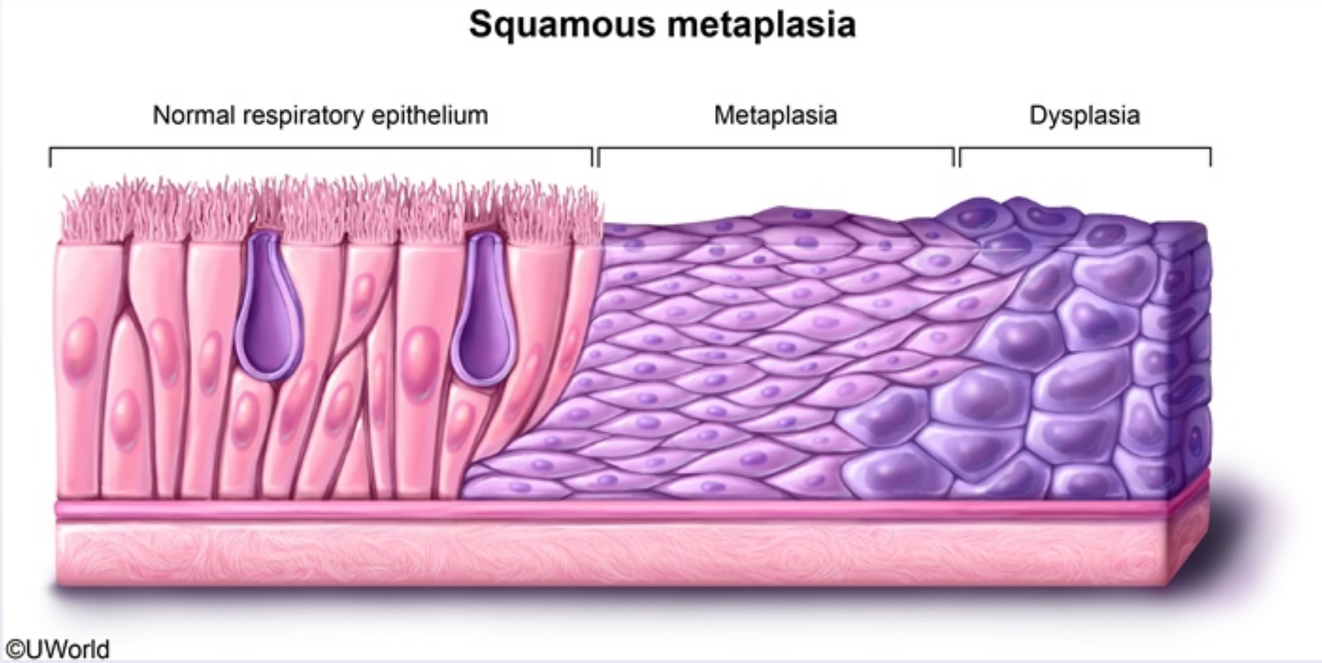

The esophagus is normally lined by nonkeratinized, stratified squamous epithelium. However, chronic exposure to acidic stomach contents can damage the epithelial surface and result in the release of cytokines and growth factors that cause esophageal stem cells to **differentiate** into an **alternate epithelial cell type** (intestine-like columnar cells) better suited for an acidic environment. The substitution of one differentiated epithelial cell type for another in response to adverse environmental conditions is called **metaplasia**.

Metaplasia is also seen in the trachea and **bronchi of chronic cigarette smokers** where the irritative effect of smoke leads to the replacement of normal ciliated columnar cells with heartier stratified squamous epithelium. Although this substitution reduces epithelial injury, it also eliminates the cell types that contain cilia and produce mucus, which increases the risk of respiratory infection.

Metaplasia is a reversible condition, but continued environmental stress can lead to **malignant transformation** (metaplasia → dysplasia → invasive cancer). For instance, the metaplasia seen in the distal esophagus in response to chronic acid exposure (Barrett esophagus) is

©UWorld

The esophagus is normally lined by nonkeratinized, stratified squamous epithelium. However, chronic exposure to acidic stomach contents can damage the epithelial surface and result in the release of cytokines and growth factors that cause esophageal stem cells to **differentiate** into an **alternate epithelial cell type** (intestine-like columnar cells) better suited for an acidic environment. The substitution of one differentiated epithelial cell type for another in response to adverse environmental conditions is called **metaplasia**.

Metaplasia is also seen in the trachea and **bronchi of chronic cigarette smokers** where the irritative effect of smoke leads to the replacement of normal ciliated columnar cells with heartier stratified squamous epithelium. Although this substitution reduces epithelial injury, it also eliminates the cell types that contain cilia and produce mucus, which increases the risk of respiratory infection.

Metaplasia is a reversible condition, but continued environmental stress can lead to **malignant transformation** (metaplasia → dysplasia → invasive cancer). For instance, the metaplasia seen in the distal esophagus in response to chronic acid exposure (Barrett esophagus) is associated with a high risk of malignant transformation into esophageal adenocarcinoma.

(Choice B) Psoriasis is characterized by hyperplasia, an increase in the number of cells within a tissue due to hormones or growth factors. Histology will show hyperproliferation of the dermis with epidermal thickening (acanthosis) and prolonged downward thickenings between dermal papillae ("rete ridges").

(Choice C) Irregular moles (eg, melanoma, atypical mole) are likely to contain dysplastic cells. Dysplasia is characterized by abnormal epithelial cellular architecture and irregular cellular growth. In metaplasia, one mature, differentiated cell type is replaced by another.

(Choice D) Hypertrophy is an increase in the size, but not number, of cells. Left ventricular hypertrophy can occur with aortic stenosis due to higher systolic pressures.

(Choice E) Atrophy is a reduction in cell size and number; it can occur in skeletal muscles following a period of immobility (eg, bedbound patient).

Educational objective:
Metaplasia is the substitution of one differentiated cell type for another due to the presence of an adverse environmental stimulus. It is often seen in the bronchi of chronic cigarette smokers (substitution of columnar for stratified squamous cells) and the distal esophagus of patients with chronic gastroesophageal reflux (substitution of stratified squamous with columnar cells). Metaplasia can lead to dysplasia and malignant transformation.

associated with a high risk of malignant transformation into esophageal adenocarcinoma.

(Choice B) Psoriasis is characterized by hyperplasia, an increase in the number of cells within a tissue due to hormones or growth factors. Histology will show hyperproliferation of the dermis with epidermal thickening (acanthosis) and prolonged downward thickenings between dermal papillae ("rete ridges").

(Choice C) Irregular moles (eg, melanoma, atypical mole) are likely to contain dysplastic cells. Dysplasia is characterized by abnormal epithelial cellular architecture and irregular cellular growth. In metaplasia, one mature, differentiated cell type is replaced by another.

(Choice D) Hypertrophy is an increase in the size, but not number, of cells. Left ventricular hypertrophy can occur with aortic stenosis due to higher systolic pressures.

(Choice E) Atrophy is a reduction in cell size and number; it can occur in skeletal muscles following a period of immobility (eg, bedbound patient).

Educational objective:
Metaplasia is the substitution of one differentiated cell type for another due to the presence of an adverse environmental stimulus. It is often seen in the bronchi of chronic cigarette smokers (substitution of columnar for stratified squamous cells) and the distal esophagus of patients with chronic gastroesophageal reflux (substitution of stratified squamous with columnar cells). Metaplasia can lead to dysplasia and malignant transformation.

References

- Common questions about Barrett esophagus.
- Recent developments in pathogenesis, diagnosis and therapy of Barrett's esophagus.
- Squamous metaplasia is increased in the bronchial epithelium of smokers with chronic obstructive pulmonary disease.

Pathology	Miscellaneous (Multisystem)	Gastroesophageal reflux disease
Subject	System	Topic

Copyright © UWorld. All rights reserved.

Settings

1
2
3
4
5
6
7
8
9
10
11

Item 4 of 11
Question Id: 285

Mark | Previous | Next | Full Screen | Tutorial | Lab Values | Notes | Calculator | Reverse Color | Text Zoom | Settings

Exhibit Display

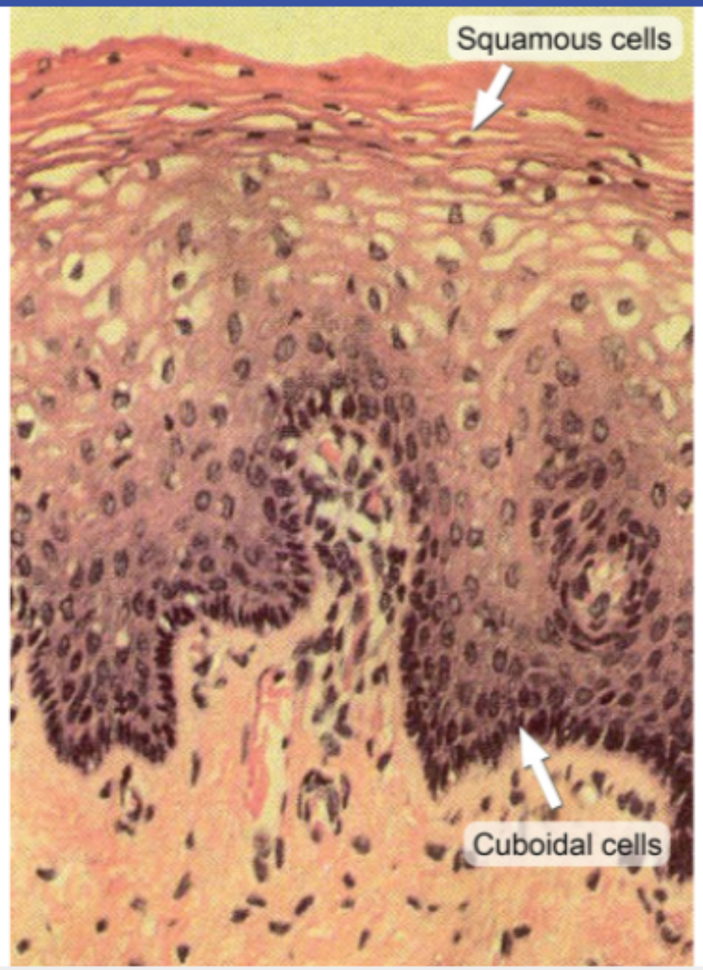

Zoom In | Zoom Out | Reset | Add To New Card | Existing Card

(Choice C) Irregular moles (eg, melanoma, atypical mole) are likely to contain dysplastic cells. Dysplasia is characterized by abnormal epithelial

Block Time Remaining: 00:00:06
TUTOR

3 | Feedback | Suspend | End Block

Settings

1
2
3
4
5
6
7
8
9
10
11

Item 4 of 11
Question Id: 285

Mark | Previous | Next | Full Screen | Tutorial | Lab Values | Notes | Calculator | Reverse Color | Text Zoom | Settings

Exhibit Display

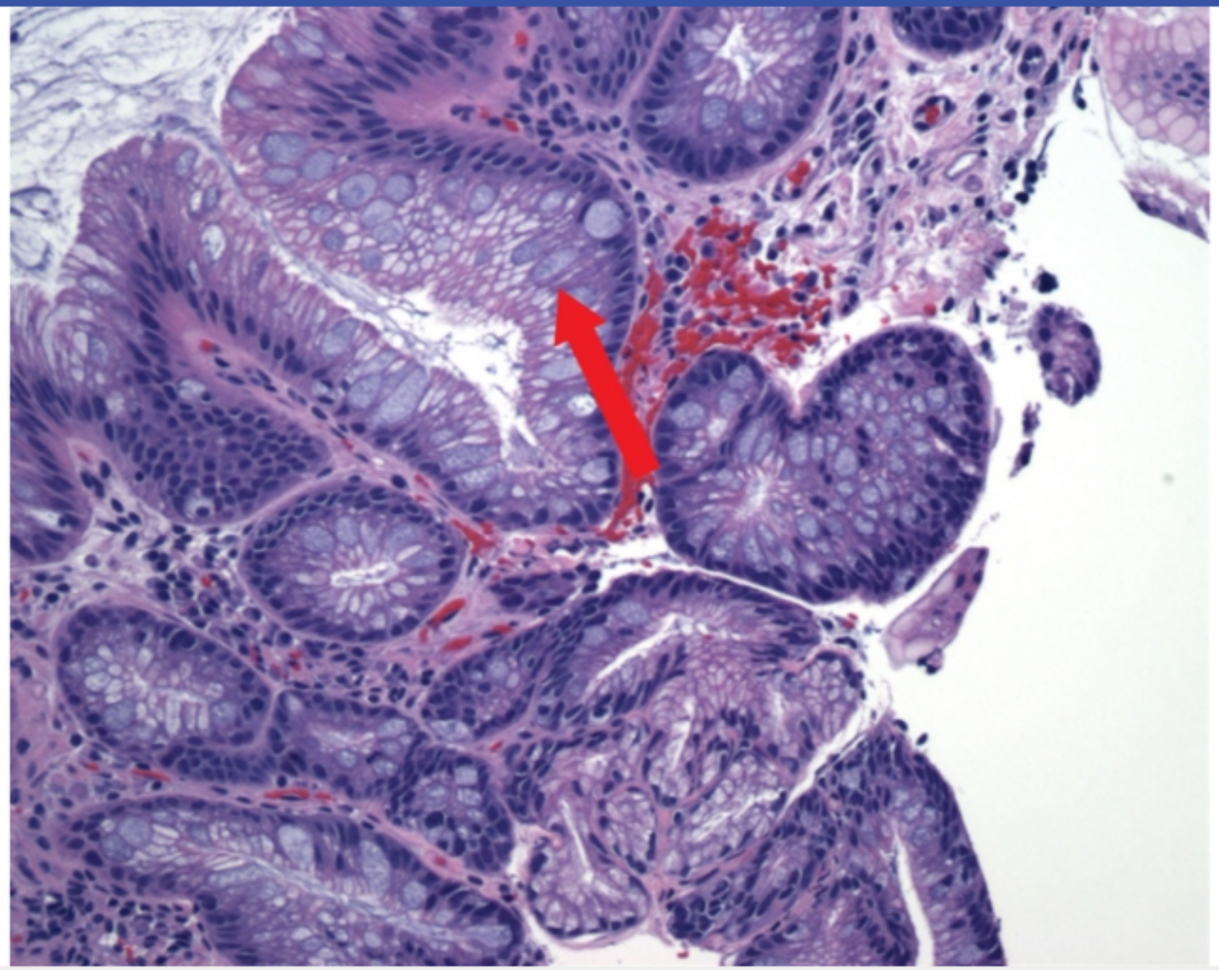

Zoom In | Zoom Out | Reset | Add To New Card | Existing Card

(Choice C) Irregular moles (eg, melanoma, atypical mole) are likely to contain dysplastic cells. Dysplasia is characterized by abnormal epithelial

Block Time Remaining: 00:00:06
TUTOR

3 | Feedback | Suspend | End Block

Settings

1
2
3
4
5
6
7
8
9
10
11

Item 5 of 11
Question Id: 11949

Mark | Previous | Next | Full Screen | Tutorial | Lab Values | Notes | Calculator | Reverse Color | Text Zoom | Settings

A 3-year-old boy is brought to the office by his parents due to constipation. The boy previously had soft stools 1-2 times daily. However, over the past 3 months, his bowel movements have decreased to 1 stool every 3-4 days with significant straining and production of hard stool balls. The boy has intermittent diffuse abdominal pain and increased irritability, but these symptoms have not affected his overall appetite. Family history is notable for a maternal aunt with celiac disease and a paternal grandmother with "thyroid problems." Four months ago, the boy and his parents moved into a house owned by their family for generations, and the parents are worried that the stress of the move might be contributing to his symptoms. Height and weight have been tracking appropriately. Physical examination shows a pale, tired boy with palpable stool in his abdomen but no abdominal tenderness. Which of the following is the most appropriate diagnostic test for this patient?

A. Anorectal manometry

B. Blood lead level

C. Serum electrolytes

D. Serum thyroid-stimulating hormone

E. Serum tissue transglutaminase

Submit

Block Time Remaining: 00:00:07
TUTOR

2 | Feedback | Suspend | End Block

A 3-year-old boy is brought to the office by his parents due to constipation. The boy previously had soft stools 1-2 times daily. However, over the past 3 months, his bowel movements have decreased to 1 stool every 3-4 days with significant straining and production of hard stool balls. The boy has intermittent diffuse abdominal pain and increased irritability, but these symptoms have not affected his overall appetite. Family history is notable for a maternal aunt with celiac disease and a paternal grandmother with "thyroid problems." Four months ago, the boy and his parents moved into a house owned by their family for generations, and the parents are worried that the stress of the move might be contributing to his symptoms. Height and weight have been tracking appropriately. Physical examination shows a pale, tired boy with palpable stool in his abdomen but no abdominal tenderness. Which of the following is the most appropriate diagnostic test for this patient?

A. Anorectal manometry (5%)
✓ B. Blood lead level (81%)
C. Serum electrolytes (2%)
D. Serum thyroid-stimulating hormone (7%)
E. Serum tissue transglutaminase (3%)

Omitted
Correct answer
B

81%
Answered correctly

02 secs
Time Spent

03/31/2020
Last Updated

Explanation

Complications of lead poisoning in children

Complications of lead poisoning in children	
Neurologic	• Loss of milestones/cognitive impairment • Behavioral problems • Encephalopathy
Gastrointestinal	• Constipation • Abdominal pain • Decreased vitamin D metabolism
Renal	• Interstitial nephritis
Hematologic	• Anemia

©UWorld

This patient's constipation, abdominal pain, irritability, and pallor (suggesting anemia) are most likely due to lead poisoning. Policy efforts resulted in the elimination of lead, a toxic metal, in gasoline (1985) and paint (1977). Current lead exposure occurs through contact with **dust/paint in homes built before 1978**; this is the most likely cause of this patient's condition given the onset of symptoms after moving.

Lead binds to sulfhydryl groups on proteins, replaces calcium in calcium-dependent cellular functions, and directly inhibits enzymes in heme synthesis. Symptoms of lead poisoning are neurologic (**cognitive impairment**, irritability), gastrointestinal (**constipation**, **abdominal pain**), renal (**interstitial nephritis**), and hematologic (**anemia**).

Risk factors include having a sibling with prior elevated lead levels and living in older homes with recent renovation/construction. Because irreversible neurodevelopmental effects occur during exposure to low lead levels, screening is recommended for young children at high risk. Diagnosis is made by measuring the **blood lead level**. Urine δ-aminolevulinic acid (heme synthesis substrate) is also elevated.

This patient's constipation, abdominal pain, irritability, and pallor (suggesting anemia) are most likely due to lead poisoning. Policy efforts resulted in the elimination of lead, a toxic metal, in gasoline (1985) and paint (1977). Current lead exposure occurs through contact with **dust/paint in homes built before 1978**; this is the most likely cause of this patient's condition given the onset of symptoms after moving.

Lead binds to sulfhydryl groups on proteins, replaces calcium in calcium-dependent cellular functions, and directly inhibits enzymes in heme synthesis. Symptoms of lead poisoning are neurologic (**cognitive impairment**, irritability), gastrointestinal (**constipation**, **abdominal pain**), renal (**interstitial nephritis**), and hematologic (**anemia**).

Risk factors include having a sibling with prior elevated lead levels and living in older homes with recent renovation/construction. Because irreversible neurodevelopmental effects occur during exposure to low lead levels, screening is recommended for young children at high risk. Diagnosis is made by measuring the **blood lead level**. Urine δ-aminolevulinic acid (heme synthesis substrate) is also elevated.

(Choice A) Hirschsprung disease typically presents in the newborn period with bilious vomiting and failure to pass meconium. Anorectal manometry measures rectal pressure via rectal catheter and shows absent relaxation of the internal anal sphincter. The diagnosis of Hirschsprung disease is confirmed by rectal biopsy.

(Choice C) Hypokalemia and hypercalcemia can present with constipation. However, patients with hypokalemia exhibit muscle weakness or arrhythmias, whereas hypercalcemia is accompanied by muscle weakness, confusion, and renal insufficiency.

(Choice D) Hypothyroidism can cause constipation, and primary hypothyroidism is associated with elevated TSH. However, constipation due to hypothyroidism is usually accompanied by other symptoms, such as decreased growth velocity and short stature in children.

(Choice E) Tissue transglutaminase is a screening test for celiac disease, which typically presents with diarrhea, weight loss, and abdominal pain. Some patients present with constipation instead of diarrhea. However, given this patient's appropriate growth and symptom onset after the recent move, lead poisoning is the more likely diagnosis.

Educational objective:
Lead poisoning can cause neurologic, gastrointestinal, renal, and hematologic complications. Although symptoms can be vague, lead poisoning should be suspected if these symptoms arise while residing in a home built before 1978. Diagnosis is made by measuring the patient's blood lead level.

Settings

1
2
3
4
5
6
7
8
9
10
11

Item 5 of 11
Question Id: 11949

Mark | Previous | Next | Full Screen | Tutorial | Lab Values | Notes | Calculator | Reverse Color | Text Zoom | Settings

Exhibit Display

Hirschsprung disease

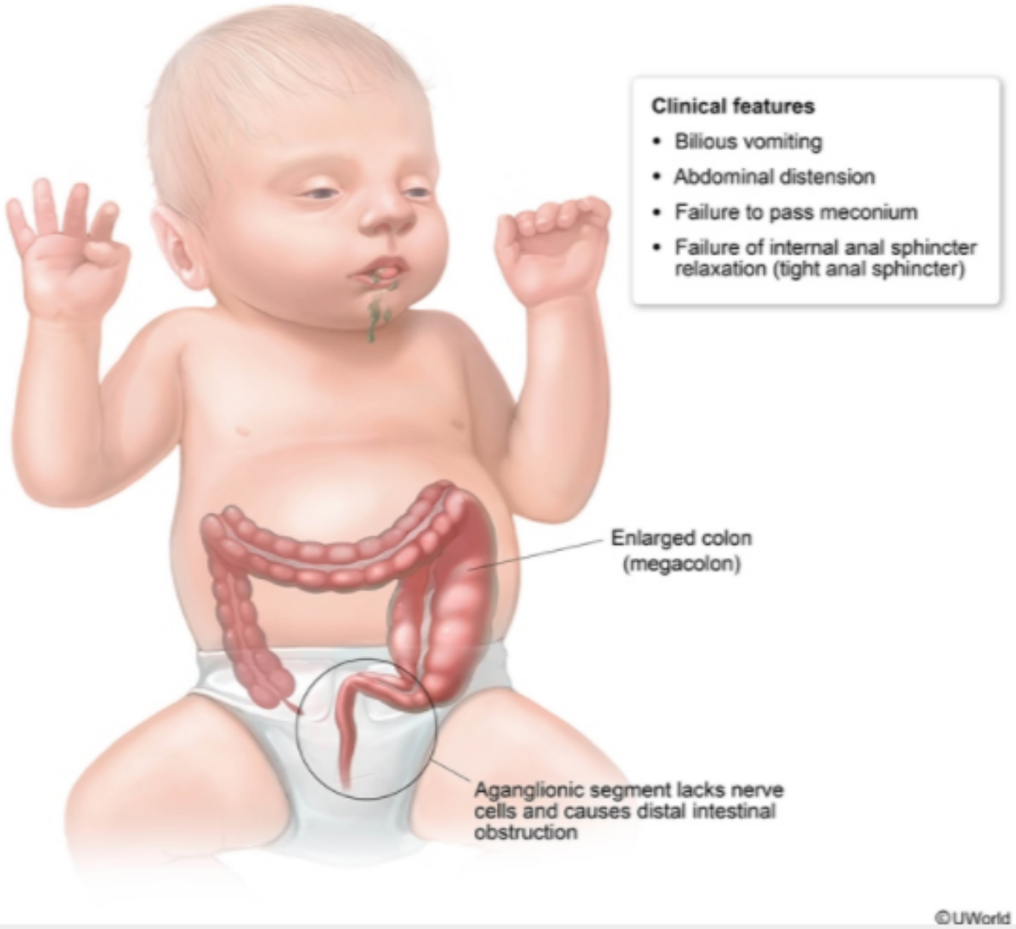

Zoom In | Zoom Out | Reset | Add To New Card | Existing Card

Block Time Remaining: 00:00:08
TUTOR

2 | Feedback | Suspend | End Block

Risk factors include having a sibling with prior elevated lead levels and living in older homes with recent renovation/construction. Because

Exhibit Display

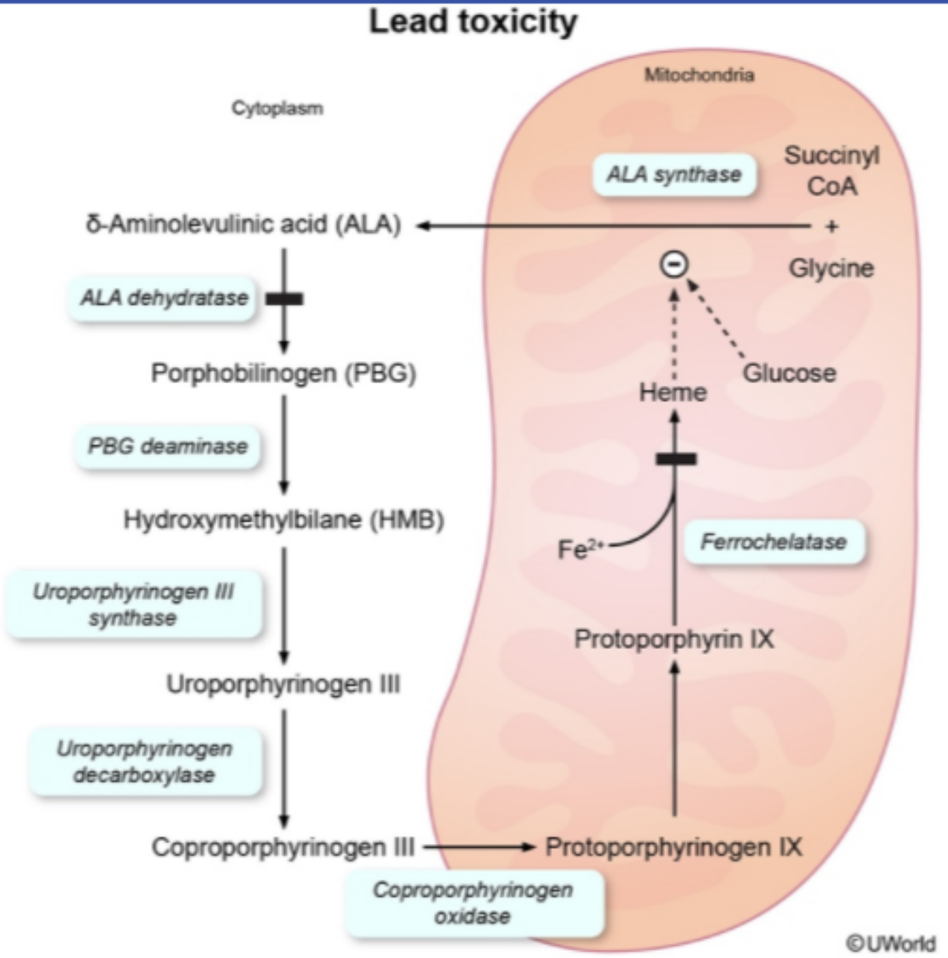

Zoom In | Zoom Out | Reset | Add To New Card | Existing Card

Settings

1
2
3
4
5
6
7
8
9
10
11

Item 6 of 11
Question Id: 862

Mark | Previous | Next | Full Screen | Tutorial | Lab Values | Notes | Calculator | Reverse Color | Text Zoom | Settings

A 50-year-old woman who has had mild myopia for decades comes to the office for a routine physical examination. The patient has no chronic medical conditions and eats a healthy diet consisting of a variety of organically grown foods. She is excited because she rarely has to wear glasses or contacts anymore. Her visual acuity at 20 feet is 20/30 in both eyes without wearing her glasses. Which of the following conditions has the same etiology as the changes causing this patient's visual improvement?

A. Actinic keratosis
B. Angle-closure glaucoma
C. Coronary atherosclerosis
D. Femoral head osteonecrosis
E. Skin wrinkles

Submit

Block Time Remaining: 00:00:09
TUTOR

5 | Feedback | Suspend | End Block

A 50-year-old woman who has had mild myopia for decades comes to the office for a routine physical examination. The patient has no chronic medical conditions and eats a healthy diet consisting of a variety of organically grown foods. She is excited because she rarely has to wear glasses or contacts anymore. Her visual acuity at 20 feet is 20/30 in both eyes without wearing her glasses. Which of the following conditions has the same etiology as the changes causing this patient's visual improvement?

A. Actinic keratosis (10%)

B. Angle-closure glaucoma (14%)

C. Coronary atherosclerosis (7%)

D. Femoral head osteonecrosis (1%)

✓ E. Skin wrinkles (65%)

Omitted
Correct answer
E

65%
Answered correctly

02 secs
Time Spent

04/16/2020
Last Updated

Explanation

Interaction between presbyopia & myopia

Image focuses

Settings

1
2
3
4
5
6
7
8
9
10
11

Item 6 of 11
Question Id: 862

Mark | Previous | Next | Full Screen | Tutorial | Lab Values | Notes | Calculator | Reverse Color | Text Zoom | Settings

Interaction between presbyopia & myopia

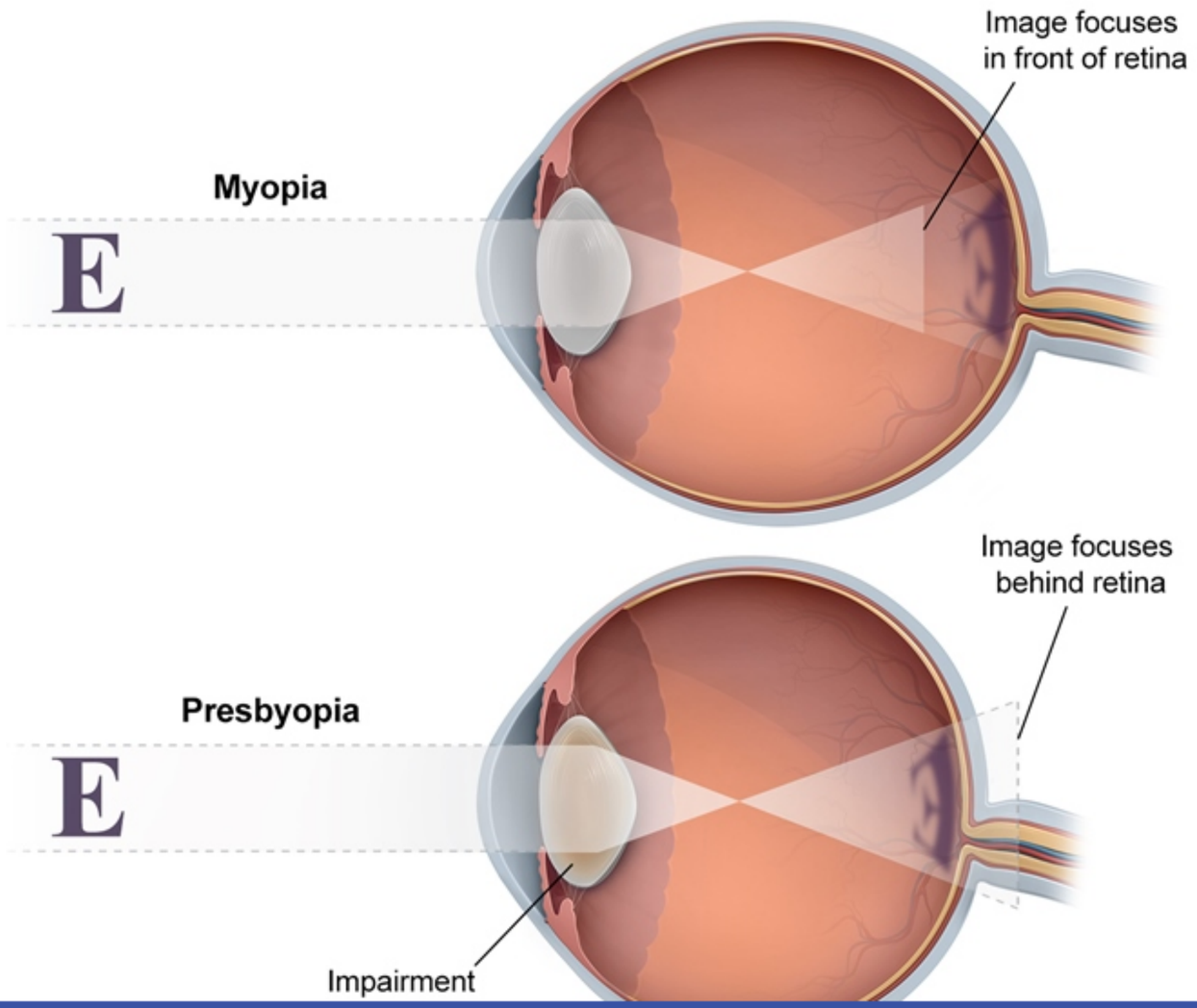

Block Time Remaining: 00:00:10
TUTOR

5 | Feedback | Suspend | End Block

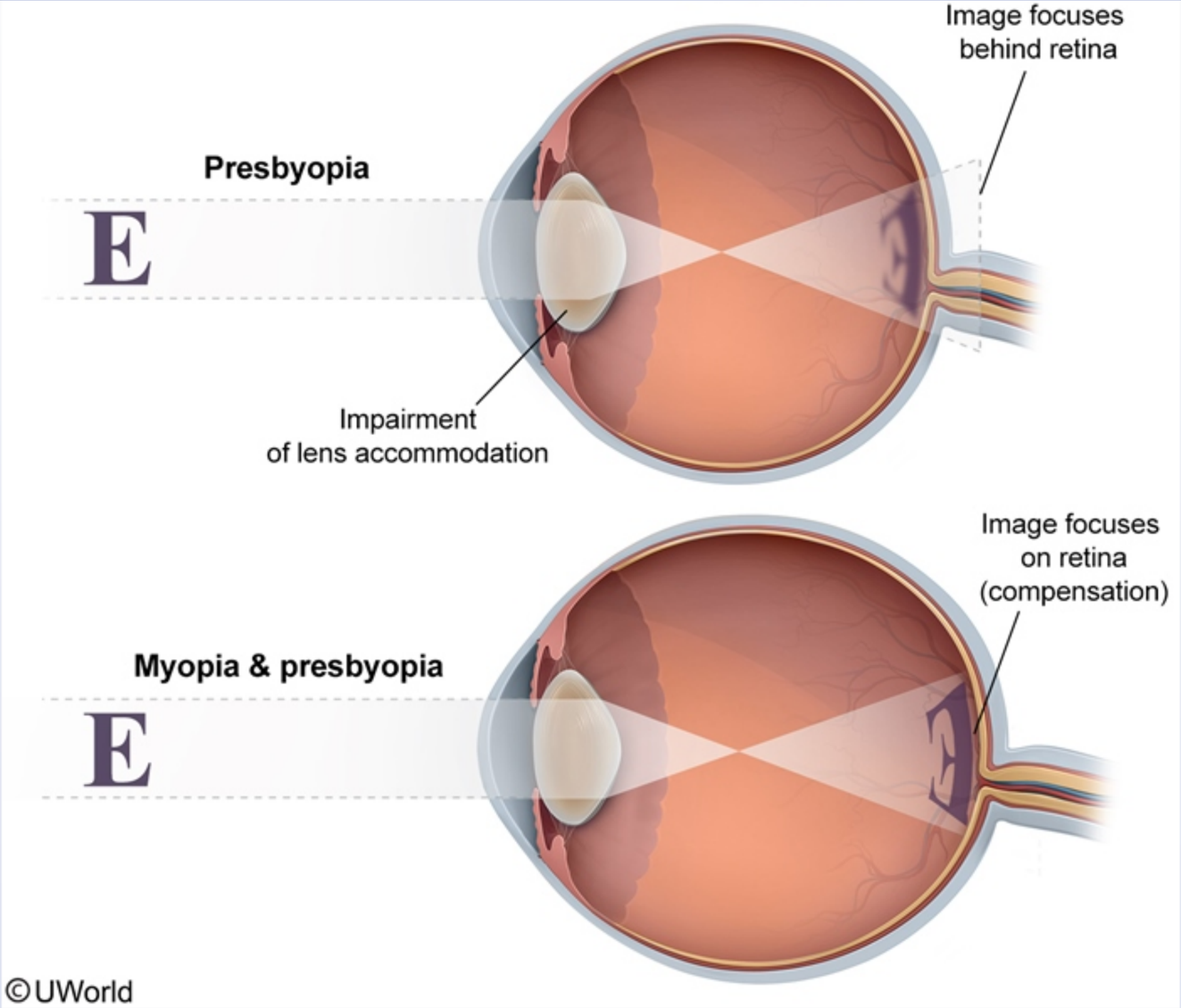

The improvement in this patient's mild myopia is likely due to age-related changes. Normally, in **accommodation**, when focusing on near objects

The improvement in this patient's mild myopia is likely due to age-related changes. Normally, in **accommodation**, when focusing on near objects (eg, reading), ciliary muscle contraction relaxes the zonular fibers, allowing the lens to become more convex so the image focuses **on the retina**.

Starting around age 40-50, almost all individuals develop an inability to focus on near objects. In this condition, called presbyopia, progressive denaturation of lens proteins and changes in lens curvature cause the lens to become less elastic and lose its accommodating power. In most patients, this causes the image of near objects to focus **behind the retina** resulting in difficulty reading fine print and the need to hold objects farther away in order to see them clearly. However, in patients with mild **myopia** (increased axial length with an image focused **in front of the retina**), presbyopia can **compensate** for myopia by displacing the image backward, so that it focuses on the retina. These patients often note improvement in visual acuity with age as presbyopia develops.

Skin rhytides (wrinkles) are also directly caused by chronological aging (with a contribution from the harmful effects of ultraviolet light). With aging, skin becomes atrophic and fragile, with reduced elasticity and subdermal fat. There is dermal and epidermal thinning, flattening of the dermoepidermal junction, a decreased number of fibroblasts, and reduced synthesis and increased breakdown of collagen and elastin.

(Choices A, B, and C) Although age is a risk factor for actinic keratoses, angle-closure glaucoma, and atherosclerosis, age-related changes themselves do not cause these conditions. Actinic keratoses (ie, premalignant lesions increasing squamous cell carcinoma risk) are rough, scaly, erythematous papules on sun-exposed areas that result from ultraviolet damage. Angle-closure glaucoma occurs due to impaired aqueous humor flow. Atherosclerosis is primarily attributable to hyperlipidemia, hypertension, and genetic (familial) predisposition.

(Choice D) Femoral head osteonecrosis is associated with vasculitis (lupus), corticosteroid therapy, sickle cell disease, and alcoholism. It is not an age-related condition and can occur in children (eg, Legg-Calve-Perthes disease).

Educational objective:
Presbyopia and skin wrinkles are age-related changes. Presbyopia occurs due to denaturation of structural proteins within the lens, leading to loss of lens elasticity which can result in improved vision in patients with mild myopia. Decreased synthesis and increased breakdown of collagen and elastin contribute to the development of skin wrinkles.

Pathology	Miscellaneous (Multisystem)	Aging
Subject	System	Topic

The improvement in this patient's mild myopia is likely due to age-related changes. Normally, in **accommodation**, when focusing on near objects

Exhibit Display

Changes associated with normal aging

System	Physiologic effects	Medical complications
Cardiovascular	• ↓ maximum heart rate • Thickening & calcification of the aorta	• ↓ exercise capacity • Systolic hypertension
Gastrointestinal	• ↑ gastric acid reflux • ↓ colonic motility	• Gastroesophageal reflux disease • Chronic constipation
Urinary	• ↓ ability to concentrate urine • Impaired emptying of the bladder	• Dehydration • Urinary tract infections & incontinence
Immune	• ↓ numbers of B & T cells	• ↑ respiratory & nosocomial infections, malignancies, & autoimmune conditions
Musculoskeletal	• ↓ muscle mass • ↑ bone mineral loss	• ↑ risk of falls • ↑ fracture risk
Integumentary	• Skin atrophy • ↓ subdermal fat	• ↑ skin fragility • Skin wrinkling
Sensory	• Hardening of the ocular lens • Deterioration of auditory pathway	• Presbyopia • Presbycusis

©UWorld

Zoom In | Zoom Out | Reset | Add To New Card | Existing Card

Subject System Topic

Settings

1
2
3
4
5
6
7
8
9
10
11

Item 6 of 11
Question Id: 862

Mark | Previous | Next | Full Screen | Tutorial | Lab Values | Notes | Calculator | Reverse Color | Text Zoom | Settings

The improvement in this patient's mild myopia is likely due to age-related changes. Normally, in **accommodation**, when focusing on near objects

Exhibit Display

Occular accommodation and presbyopia

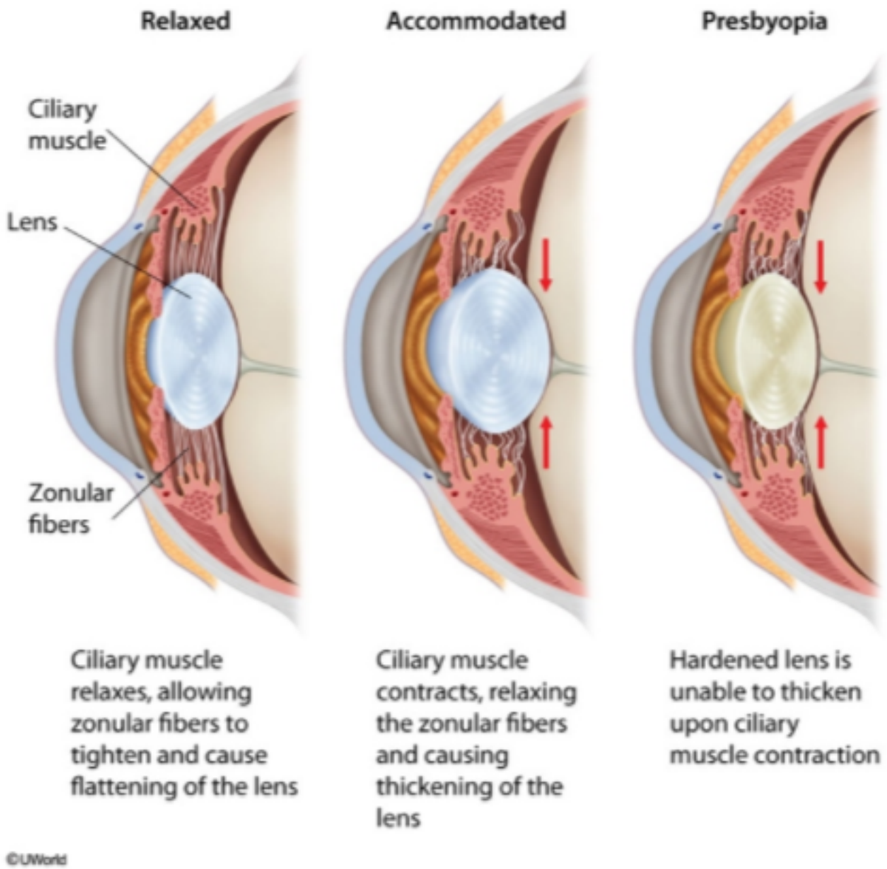

Zoom In | Zoom Out | Reset | Add To New Card | Existing Card

Subject System Topic

Block Time Remaining: 00:00:10
TUTOR

5 | Feedback | Suspend | End Block

The improvement in this patient's mild myopia is likely due to age-related changes. Normally, in **accommodation**, when focusing on near objects

Exhibit Display

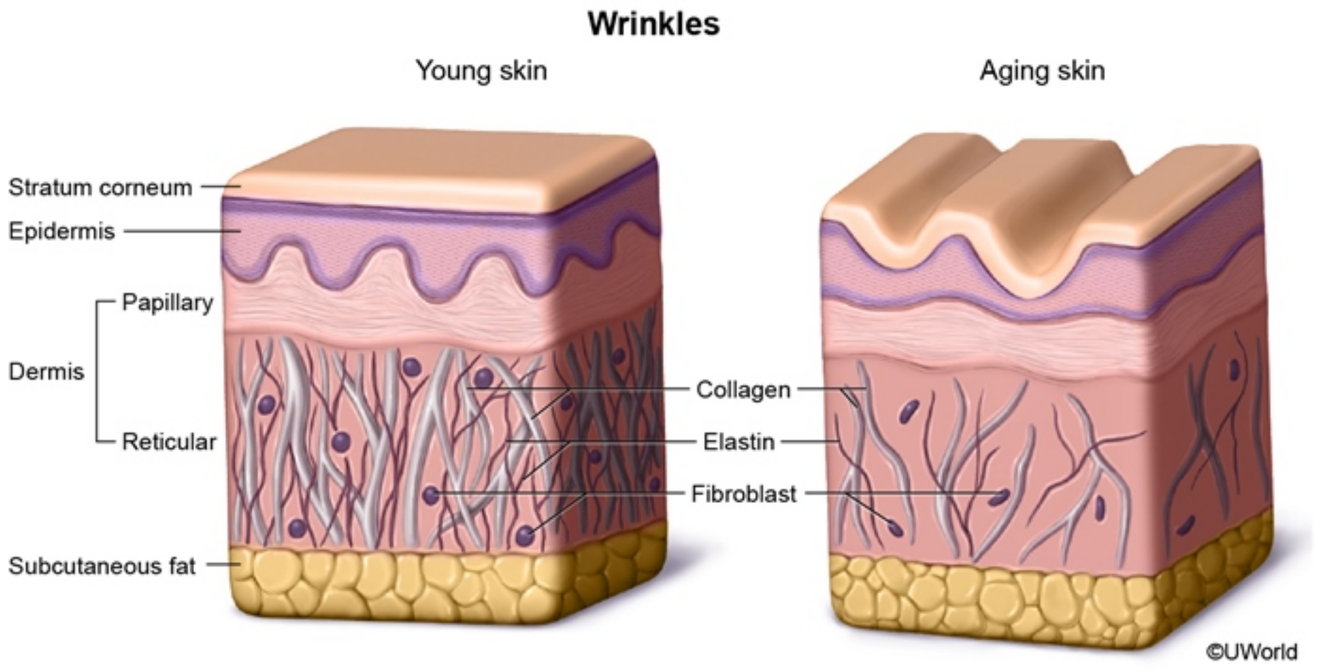

Zoom In | Zoom Out | Reset | Add To New Card | Existing Card

A 61-year-old man comes to the emergency department due to fever, chills, and a productive cough with thick, blood-tinged sputum for the past several days. His temperature is 38.8 C (102 F), blood pressure is 90/60 mm Hg, and pulse is 110/min. On examination, the patient is lethargic and ill appearing. Bronchial breath sounds and crackles are present in the right lung. Blood and sputum cultures grow *Klebsiella pneumoniae*. It is determined that the bacteria express a lipopolysaccharide on their outer membrane surface that stimulates toll-like receptors in the inflammatory cells. This in turn leads to degradation of the IκB inhibitor protein, which normally binds to a latent transcription factor found in the cytoplasm. Which of the following factors is most likely to be directly activated by the removal of this inhibitor protein?

A. Granulocyte colony-stimulating factor

B. Janus kinase 2

C. Nuclear factor-kappa B

D. Transforming growth factor-β

E. Tumor necrosis factor-α

Submit

A 61-year-old man comes to the emergency department due to fever, chills, and a productive cough with thick, blood-tinged sputum for the past several days. His temperature is 38.8 C (102 F), blood pressure is 90/60 mm Hg, and pulse is 110/min. On examination, the patient is lethargic and ill appearing. Bronchial breath sounds and crackles are present in the right lung. Blood and sputum cultures grow *Klebsiella pneumoniae*. It is determined that the bacteria express a lipopolysaccharide on their outer membrane surface that stimulates toll-like receptors in the inflammatory cells. This in turn leads to degradation of the IκB inhibitor protein, which normally binds to a latent transcription factor found in the cytoplasm. Which of the following factors is most likely to be directly activated by the removal of this inhibitor protein?

A. Granulocyte colony-stimulating factor (3%)

B. Janus kinase 2 (6%)

✓ C. Nuclear factor-kappa B (67%)

D. Transforming growth factor-β (4%)

E. Tumor necrosis factor-α (18%)

Omitted
Correct answer
C

67%
Answered correctly

05 secs
Time Spent

04/06/2020
Last Updated

Explanation

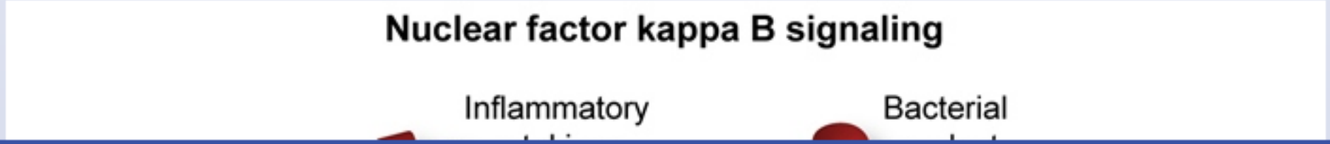

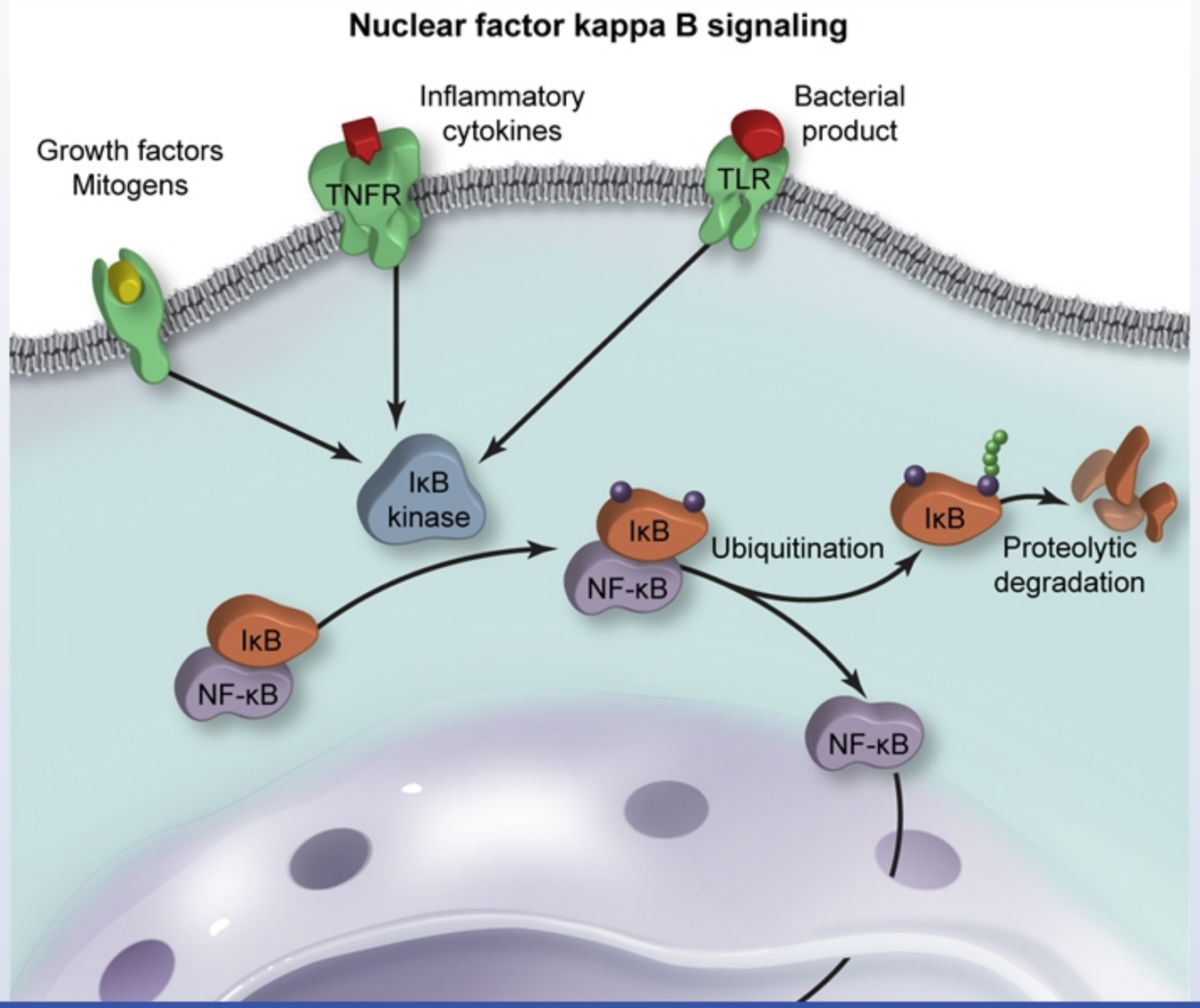
Nuclear factor kappa B signaling
Growth factors
Mitogens
Inflammatory
cytokines
Bacterial
product
TNFR
TLR
IκB
kinase
IκB
NF-κB
Ubiquitination
IκB
Proteolytic
degradation
IκB
NF-κB
NF-κB

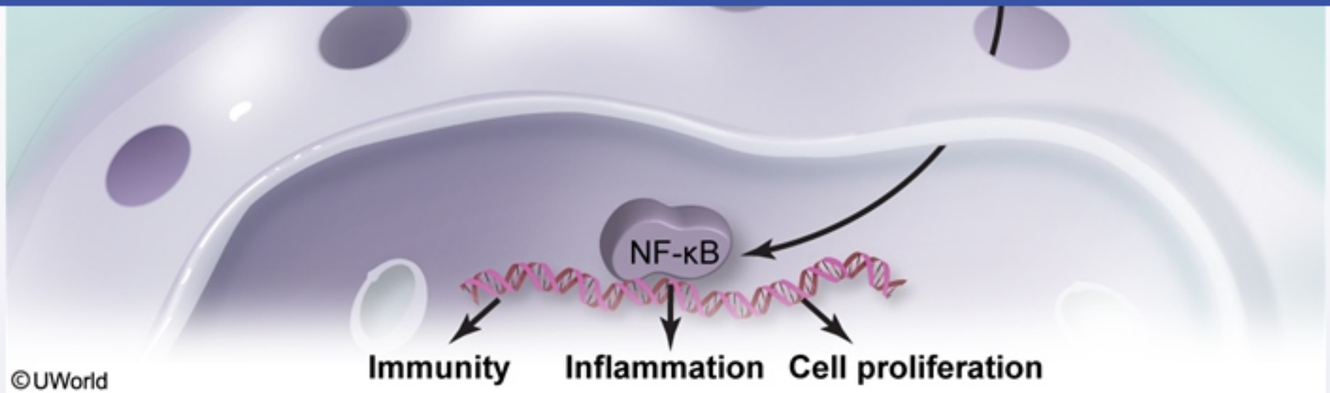

Nuclear factor-kappa B (NF-κB) is part of a family of **transcription factors** that perform a critical role in the immune response to infection and inflammation. In inflammatory cells, NF-κB is normally present in a latent, inactive state bound to its inhibitor protein, IκB. As part of the classical activation pathway, an extracellular signal, such as the binding of bacterial antigens to a toll-like receptor, causes activation of **IκB kinase**. This results in **ubiquitination** and subsequent destruction of IκB with the release of free NF-κB. Once free, NF-κB enters the nucleus and promotes the synthesis of a number of **inflammatory proteins** such as cytokines, acute phase reactants, cell adhesion molecules, and leukocyte-related growth factors. The inflammatory cascade is self-limiting as NF-κB also stimulates the transcription of more IκB, ultimately rebinding the freed NF-κB.

(Choices A and E) Granulocyte colony-stimulating factor (G-CSF) is the principal protein that stimulates the production and release of neutrophils from the bone marrow. Tumor necrosis factor-α (TNF-α) plays a major role in the response to infection by increasing neutrophil chemotaxis and stimulating macrophage phagocytosis. Although NF-κB upregulates transcription of G-CSF and TNF-α, IκB degradation is not directly involved in the activation of these factors.

(Choice B) Janus kinase 2 (JAK2) is a tyrosine kinase involved in the signaling pathway for myeloproliferation. Constituent activation of JAK2 is associated with polycythemia vera, essential thrombocytosis, and myelofibrosis. It does not play a major role in the immune response to infection.

(Choice D) Although transforming growth factor-β (TGF-β) also has a role in the immune response and is triggered by inflammatory pathways, it is complexed to TGF-β binding protein and latency-associated peptide, not IκB.

Educational objective:

results in **ubiquitination** and subsequent destruction of IκB with the release of free NF-κB. Once free, NF-κB enters the nucleus and promotes the synthesis of a number of **inflammatory proteins** such as cytokines, acute phase reactants, cell adhesion molecules, and leukocyte-related growth factors. The inflammatory cascade is self-limiting as NF-κB also stimulates the transcription of more IκB, ultimately rebinding the freed NF-κB.

(Choices A and E) Granulocyte colony-stimulating factor (G-CSF) is the principal protein that stimulates the production and release of neutrophils from the bone marrow. Tumor necrosis factor-α (TNF-α) plays a major role in the response to infection by increasing neutrophil chemotaxis and stimulating macrophage phagocytosis. Although NF-κB upregulates transcription of G-CSF and TNF-α, IκB degradation is not directly involved in the activation of these factors.

(Choice B) Janus kinase 2 (JAK2) is a tyrosine kinase involved in the signaling pathway for myeloproliferation. Constituent activation of JAK2 is associated with polycythemia vera, essential thrombocytosis, and myelofibrosis. It does not play a major role in the immune response to infection.

(Choice D) Although transforming growth factor-β (TGF-β) also has a role in the immune response and is triggered by inflammatory pathways, it is complexed to TGF-β binding protein and latency-associated peptide, not IκB.

Educational objective:
Nuclear factor-kappa B (NF-κB) is a transcription factor with a critical role in the immune response to infection. NF-κB is normally present in the cytoplasm in a latent, inactive state bound to its inhibitor protein, IκB. Extracellular substances such as lipopolysaccharide can initiate a signal cascade that results in the destruction of IκB and translocation of free NF-κB to the nucleus.

References

- The nuclear factor NF-?B pathway in inflammation.
- Regulation and function of NF-kappaB transcription factors in the immune system.

Pathology	Miscellaneous (Multisystem)	Nuclear factor kappa b
Subject	System	Topic

Copyright © UWorld. All rights reserved.

Settings

1
2
3
4
5
6
7
8
9
10
11

Item 8 of 11
Question Id: 297

Mark | Previous | Next | Full Screen | Tutorial | Lab Values | Notes | Calculator | Reverse Color | Text Zoom | Settings

A 46-year-old Caucasian male presents to your office with a slowly growing neck mass. The mass is stony hard on palpation and seems to be fixed to the adjacent tissues. After initial evaluation, combination chemotherapy is prescribed to the patient. Several weeks later the mass significantly decreases in size, and biopsy demonstrates many shrunken eosinophilic cells within the tumor. Which of the following substances released from mitochondria most likely triggered the observed cellular changes?

A. Hemosiderin
B. Fas (CD95)
C. Cytochrome c
D. Succinate dehydrogenase
E. Superoxide dismutase
F. Lipoxygenase

Submit

Block Time Remaining: 00:00:15
TUTOR

1 | Feedback | Suspend | End Block

A 46-year-old Caucasian male presents to your office with a slowly growing neck mass. The mass is stony hard on palpation and seems to be fixed to the adjacent tissues. After initial evaluation, combination chemotherapy is prescribed to the patient. Several weeks later the mass significantly decreases in size, and biopsy demonstrates many shrunken eosinophilic cells within the tumor. Which of the following substances released from mitochondria most likely triggered the observed cellular changes?

- A. Hemosiderin (1%)
- B. Fas (CD95) (11%)
- ✓ C. Cytochrome c (68%)
- D. Succinate dehydrogenase (2%)
- E. Superoxide dismutase (11%)
- F. Lipoxygenase (3%)

Omitted
Correct answer
C

68%
Answered correctly

01 sec
Time Spent

02/03/2020
Last Updated

Explanation

Apoptosis is a means of carefully regulated cell death in which the cell activates enzymes to degrade its own nuclear DNA and proteins. Although the cell membrane remains intact during apoptosis, the cell becomes an appealing target for phagocytosis. Because no cell contents are leaked into the surrounding tissue, there is no associated inflammation.

The process of apoptosis is separated into an initiation phase and an execution phase. During the initiation phase, protein hydrolyzing caspases

Apoptosis is a means of carefully regulated cell death in which the cell activates enzymes to degrade its own nuclear DNA and proteins. Although the cell membrane remains intact during apoptosis, the cell becomes an appealing target for phagocytosis. Because no cell contents are leaked into the surrounding tissue, there is no associated inflammation.

The process of apoptosis is separated into an initiation phase and an execution phase. During the initiation phase, protein-hydrolyzing caspases are activated. In the execution phase, these caspases bring about the cell death by cleaving cellular proteins and activating DNAses.

The initiation of apoptosis occurs via signals from two separate pathways: the intrinsic (mitochondrial) pathway and the extrinsic (death receptor) pathway. In the intrinsic pathway, the mitochondria become more permeable and pro-apoptotic substances are released into the cytoplasm in response to stress or the cessation of survival signals. Once the cell is exposed to stress or the cessation of survival signals, the anti-apoptotic proteins Bcl-2 and Bcl-x that reside in the mitochondrial membranes and cytoplasm are replaced with pro-apoptotic proteins such as Bak, Bax, and Bim. The pro-apoptotic proteins allow for the increased permeability of the mitochondria, which results in the release of caspase-activating substances like cytochrome c.

(Choice A) Hemosiderin accumulation is common in patients who have hemolytic anemia or who undergo frequent blood transfusions. It is not associated with apoptosis.

(Choice B) The extrinsic pathway requires engagement of death receptors on the cell surface. These death receptors are in the tumor necrosis factor receptor family, with the type 1 TNF receptor (TNFR1) and a related protein named Fas (CD95) the two best known members of this family. After cross-linkage of Fas with its ligand, multiple molecules of Fas come together to form a binding site for a death-domain containing adapter protein called FADD. FADD then binds an inactive form of a caspase, again bringing multiple caspase proteins together that through a cascade effect eventually induce caspase activation.

(Choice D) Succinate dehydrogenase is a mitochondrial enzyme in the electron transport chain that acts by oxidizing succinate into fumarate and reducing FAD to $FADH_2$. This enzyme is not involved in apoptosis.

(Choice E) Superoxide dismutase catalyzes the reduction of superoxide anions to hydrogen peroxide. This enzyme is not involved in apoptosis.

(Choice F) Lipoxygenase plays a key role in the synthesis of leukotrienes, a class of inflammatory mediators.

Educational Objective:

The initiation of apoptosis occurs via signals from two separate pathways: the intrinsic (mitochondrial) pathway and the extrinsic (death receptor) pathway. In the intrinsic pathway, the mitochondria become more permeable and pro-apoptotic substances are released into the cytoplasm in response to stress or the cessation of survival signals. Once the cell is exposed to stress or the cessation of survival signals, the anti-apoptotic proteins Bcl-2 and Bcl-x that reside in the mitochondrial membranes and cytoplasm are replaced with pro-apoptotic proteins such as Bak, Bax, and Bim. The pro-apoptotic proteins allow for the increased permeability of the mitochondria, which results in the release of caspase-activating substances like cytochrome c.

(Choice A) Hemosiderin accumulation is common in patients who have hemolytic anemia or who undergo frequent blood transfusions. It is not associated with apoptosis.

(Choice B) The extrinsic pathway requires engagement of death receptors on the cell surface. These death receptors are in the tumor necrosis factor receptor family, with the type 1 TNF receptor (TNFR1) and a related protein named Fas (CD95) the two best known members of this family. After cross-linkage of Fas with its ligand, multiple molecules of Fas come together to form a binding site for a death-domain containing adapter protein called FADD. FADD then binds an inactive form of a caspase, again bringing multiple caspase proteins together that through a cascade effect eventually induce caspase activation.

(Choice D) Succinate dehydrogenase is a mitochondrial enzyme in the electron transport chain that acts by oxidizing succinate into fumarate and reducing FAD to $FADH_2$. This enzyme is not involved in apoptosis.

(Choice E) Superoxide dismutase catalyzes the reduction of superoxide anions to hydrogen peroxide. This enzyme is not involved in apoptosis.

(Choice F) Lipoxygenase plays a key role in the synthesis of leukotrienes, a class of inflammatory mediators.

Educational Objective:
Cytochrome c is a mitochondrial enzyme that activates caspases and indirectly brings about cell death through intrinsic pathway apoptosis.

Pathology	General Principles	Apoptosis
Subject	System	Topic

Copyright © UWorld. All rights reserved.

A 32-year-old woman is evaluated for pain and a mass in the right flank. Imaging studies reveal a large mass arising from the right kidney and similar smaller masses in the left kidney. Surgery to remove the right-sided tumor along with the right kidney is performed; the cut section specimen is shown in the image below.

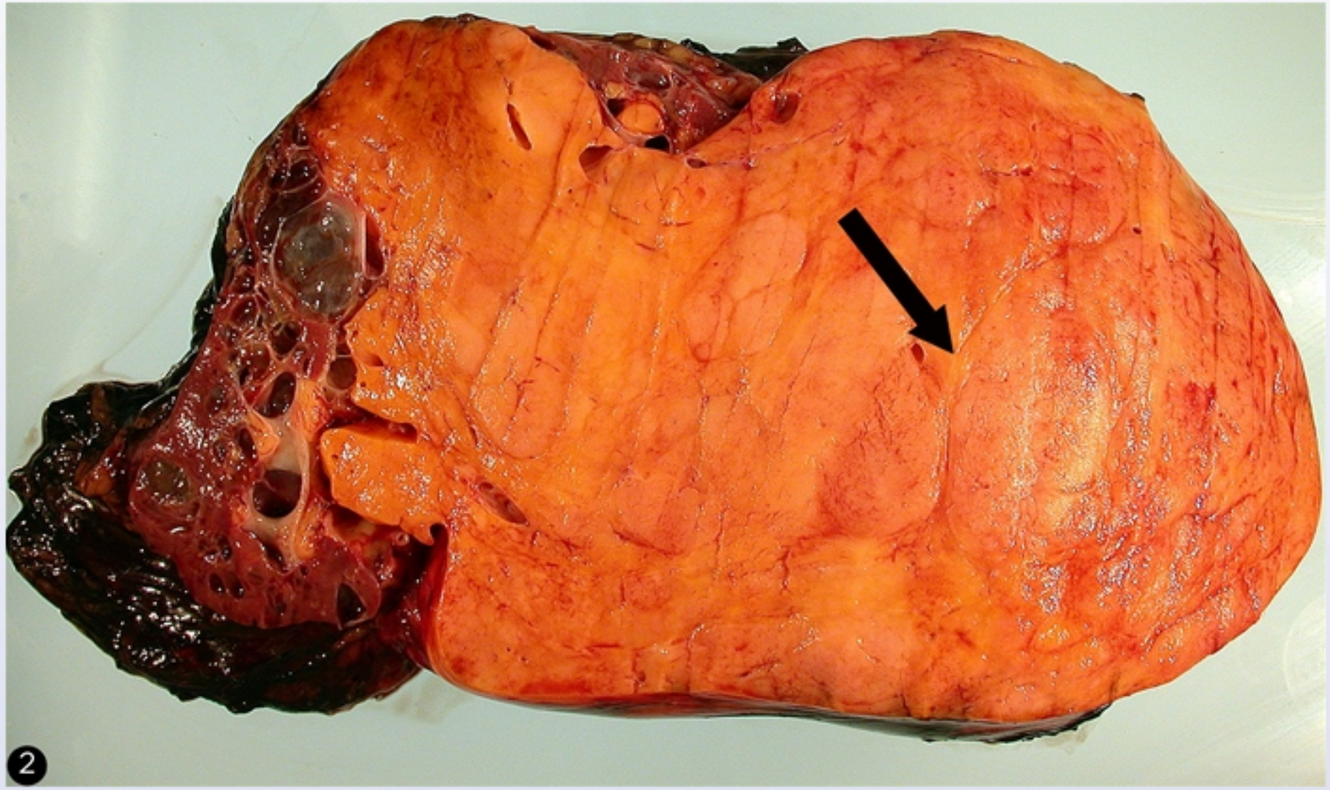

Histopathologic evaluation shows that the mass is composed of fat, smooth muscle, and blood vessels. This patient is most likely to have which of the following additional findings?

A. Bilateral acoustic neuromas

Histopathologic evaluation shows that the mass is composed of fat, smooth muscle, and blood vessels. This patient is most likely to have which of the following additional findings?

- A. Bilateral acoustic neuromas
- B. Brain hamartomas and ash-leaf skin patches
- C. Capillary angiomas of the face and choroid
- D. Cerebellar hemangioblastomas and liver cysts
- E. Multiple peripheral neurofibromas and café-au-lait skin spots
- F. Multiple telangiectasias of the skin and mucosa

Submit

Histopathologic evaluation shows that the mass is composed of fat, smooth muscle, and blood vessels. This patient is most likely to have which of the following additional findings?

- A. Bilateral acoustic neuromas (4%)
- ✓ B. Brain hamartomas and ash-leaf skin patches (45%)
- C. Capillary angiomas of the face and choroid (5%)
- D. Cerebellar hemangioblastomas and liver cysts (30%)
- E. Multiple peripheral neurofibromas and café-au-lait skin spots (9%)
- F. Multiple telangiectasias of the skin and mucosa (5%)

Omitted
Correct answer

45%
Answered correctly

03 secs
Time Spent

02/03/2020
Last Updated

Explanation

Renal angiomyolipoma is a benign tumor composed of blood vessels (angio), smooth muscle (myo), and fat (lipoma). These tumors can be diagnosed with an abdominal CT scan as the radiodensity of fat is less than that of water.

Angiomyolipomas are associated with **tuberous sclerosis**. In patients with bilateral renal angiomyolipomas, the incidence of tuberous sclerosis is 80%-90%. Tuberous sclerosis is an **autosomal dominant** condition characterized by cortical tubers and subependymal **hamartomas** in the brain, with consequent seizures and cognitive disability. Cardiac rhabdomyomas, facial angiofibromas, and leaf-shaped patches of skin lacking pigment (ash-leaf patches) can also occur.

(Choice A) Neurofibromatosis type 2 is an autosomal dominant disorder marked by bilateral acoustic neuromas. These patients may also develop multiple meningiomas, gliomas, and ependymomas of the spinal cord.

(Choice C) Sturge-Weber syndrome is a rare congenital vascular disorder characterized by a facial port-wine stain and leptomeningeal capillary-venous malformation.

(Choice D) Cerebellar hemangioblastomas, retinal hemangiomas, and liver cysts are seen in von Hippel-Lindau disease, an autosomal dominant condition. These patients are at high risk for bilateral renal cell carcinomas.

(Choice E) Neurofibromatosis type 1 is an autosomal dominant disorder characterized by neurofibromas (plexiform and solitary), optic gliomas, pigmented nodules of the iris (Lisch nodules), and cutaneous hyperpigmented macules (café-au-lait spots).

(Choice F) Patients with hereditary hemorrhagic telangiectasia (also called Osler-Weber-Rendu syndrome) develop multiple telangiectasias of the skin and mucosa. The typical presentation is recurrent epistaxis or gastrointestinal bleeding (melena).

Educational objective:
Renal angiomyolipoma is a benign tumor composed of blood vessels, smooth muscle, and fat. Bilateral renal angiomyolipomas are associated with tuberous sclerosis, an autosomal dominant condition.

References

- Tuberous sclerosis complex and renal angiomyolipoma: case report and review of the literature.

Settings

1
2
3
4
5
6
7
8
9
10
11

Item 9 of 11
Question Id: 6

Mark | Previous | Next | Full Screen | Tutorial | Lab Values | Notes | Calculator | Reverse Color | Text Zoom | Settings

Explanation

Exhibit Display

Zoom In | Zoom Out | Reset | Add To New Card | Existing Card

Block Time Remaining: 00:00:19
TUTOR

2 | Feedback | Suspend | End Block

brain, with consequent seizures and cognitive disability. Cardiac rhabdomyomas, facial angiofibromas, and leaf-shaped patches of skin lacking pigment (ash-leaf patches) can also occur.

(Choice A) Neurofibromatosis type 2 is an autosomal dominant disorder marked by bilateral acoustic neuromas. These patients may also develop multiple meningiomas, gliomas, and ependymomas of the spinal cord.

(Choice C) Sturge-Weber syndrome is a rare congenital vascular disorder characterized by a facial port-wine stain and leptomeningeal capillary-venous malformation.

(Choice D) Cerebellar hemangioblastomas, retinal hemangiomas, and liver cysts are seen in von Hippel-Lindau disease, an autosomal dominant condition. These patients are at high risk for bilateral renal cell carcinomas.

(Choice E) Neurofibromatosis type 1 is an autosomal dominant disorder characterized by neurofibromas (plexiform and solitary), optic gliomas, pigmented nodules of the iris (Lisch nodules), and cutaneous hyperpigmented macules (café-au-lait spots).

(Choice F) Patients with hereditary hemorrhagic telangiectasia (also called Osler-Weber-Rendu syndrome) develop multiple telangiectasias of the skin and mucosa. The typical presentation is recurrent epistaxis or gastrointestinal bleeding (melena).

Educational objective:
Renal angiomyolipoma is a benign tumor composed of blood vessels, smooth muscle, and fat. Bilateral renal angiomyolipomas are associated with tuberous sclerosis, an autosomal dominant condition.

References

- Tuberous sclerosis complex and renal angiomyolipoma: case report and review of the literature.
- Pictorial review of tuberous sclerosis in various organs.

Pathology	Miscellaneous (Multisystem)	Tuberous sclerosis
Subject	System	Topic

Copyright © UWorld. All rights reserved.

A 10-year-old girl is brought to clinic for laboratory follow-up. Her mother was recently diagnosed with von Hippel-Lindau (VHL) disease, and the patient received genetic testing. Examination is unremarkable. Laboratory evaluation reveals a missense mutation in the *VHL* gene. Periodic surveillance with which of the following is most likely to be of benefit in this patient?

A. Bone marrow evaluation

B. Chest radiography

C. Colonoscopy

D. Echocardiography

E. Plasma metanephrines

Submit

A 10-year-old girl is brought to clinic for laboratory follow-up. Her mother was recently diagnosed with von Hippel-Lindau (VHL) disease, and the patient received genetic testing. Examination is unremarkable. Laboratory evaluation reveals a missense mutation in the *VHL* gene. Periodic surveillance with which of the following is most likely to be of benefit in this patient?

- A. Bone marrow evaluation (6%)
- B. Chest radiography (4%)
- C. Colonoscopy (10%)
- D. Echocardiography (4%)
- ✓ E. Plasma metanephrines (74%)

Omitted
Correct answer
E

74%
Answered correctly

02 secs
Time Spent

05/12/2020
Last Updated

Explanation

Von Hippel-Lindau disease	
Etiology	• Mutation in the *VHL* tumor suppressor gene on chromosome 3 • Autosomal dominant inheritance
Manifestations	• Cerebellar & retinal hemangioblastomas • Pheochromocytoma

Von Hippel-Lindau disease	
Etiology	• Mutation in the *VHL* tumor suppressor gene on chromosome 3 • Autosomal dominant inheritance
Manifestations	• Cerebellar & retinal hemangioblastomas • Pheochromocytoma • Renal cell carcinoma (clear cell subtype)

Management	• Surveillance for associated malignancies
	  ◦ Eye/retinal examination
	  ◦ Plasma or urine metanephrines
	  ◦ MRI of the brain & spine
	  ◦ MRI of the abdomen
	• Tumor resection

Von Hippel-Lindau (VHL) disease is an **autosomal dominant** condition caused by a loss-of-function mutation in the *VHL* gene on chromosome 3. The *VHL* gene product is a tumor suppressor protein that promotes degradation of damaged proteins and aids in cell cycle regulation. Similar to other disorders affecting tumor suppressor genes (eg, familial retinoblastoma), a second, somatic mutation in this gene leads to the development of various **benign and malignant tumors** (eg, cerebellar and retinal hemangioblastomas, pheochromocytomas, renal cell carcinomas) with potentially serious complications.

Pheochromocytoma is a rare neoplasm arising from the adrenal medulla that can produce catecholamines (eg, epinephrine, norepinephrine). Patients may have hypertension, tachycardia, and sweating due to sympathetic overactivity; however, many are asymptomatic. As such, annual screening for increased urinary or **plasma metanephrines** (catecholamine breakdown products) is recommended. Likewise, screening for hemangioblastomas and renal cell carcinoma can be achieved with regular MRI and retinal examinations.

(Choice A) The results of bone marrow evaluation would be abnormal in patients with leukemia, which is not associated with VHL disease.

(Choice B) Chest radiography can identify lung metastases in a patient with a known malignancy. This patient requires evaluation for primary

Von Hippel-Lindau (VHL) disease is an **autosomal dominant** condition caused by a loss-of-function mutation in the *VHL* gene on chromosome 3. The *VHL* gene product is a tumor suppressor protein that promotes degradation of damaged proteins and aids in cell cycle regulation. Similar to other disorders affecting tumor suppressor genes (eg, familial retinoblastoma), a second, somatic mutation in this gene leads to the development of various **benign and malignant tumors** (eg, cerebellar and retinal hemangioblastomas, pheochromocytomas, renal cell carcinomas) with potentially serious complications.

Pheochromocytoma is a rare neoplasm arising from the adrenal medulla that can produce catecholamines (eg, epinephrine, norepinephrine). Patients may have hypertension, tachycardia, and sweating due to sympathetic overactivity; however, many are asymptomatic. As such, annual screening for increased urinary or **plasma metanephrines** (catecholamine breakdown products) is recommended. Likewise, screening for hemangioblastomas and renal cell carcinoma can be achieved with regular MRI and retinal examinations.

(Choice A) The results of bone marrow evaluation would be abnormal in patients with leukemia, which is not associated with VHL disease.

(Choice B) Chest radiography can identify lung metastases in a patient with a known malignancy. This patient requires evaluation for primary associated neoplasms before screening for metastases.

(Choice C) Colonoscopy is performed in patients with an inherited predisposition to colorectal cancer, such as those with hereditary nonpolyposis colorectal cancer (ie, Lynch syndrome) and familial adenomatous polyposis. VHL disease is not associated with an increased risk of colorectal cancer in younger patients.

(Choice D) Screening echocardiography is performed in patients with tuberous sclerosis complex to identify an associated cardiac rhabdomyoma. Cardiac tumors are not a significant feature of VHL disease.

Educational objective:
Von Hippel-Lindau (VHL) disease is an autosomal dominant condition caused by a mutation in a tumor suppressor gene, which is associated with the development of pheochromocytomas, retinal and cerebellar hemangioblastomas, and renal cell carcinomas. Because of the potential for serious complications from these tumors, patients with VHL should receive annual surveillance, including plasma metanephrines, abdominal imaging, ophthalmologic examination, and MRI of the brain and spine.

References

Exhibit Display

Knudson's 2-hit hypothesis

Both copies of the gene must be knocked out to promote malignancy.

Sporadic cancer:
2 acquired mutations

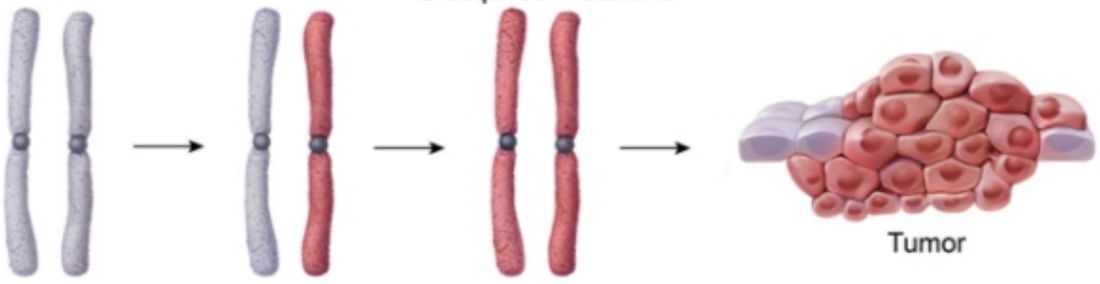

Hereditary cancer:
1 inherited and 1 acuired mutation

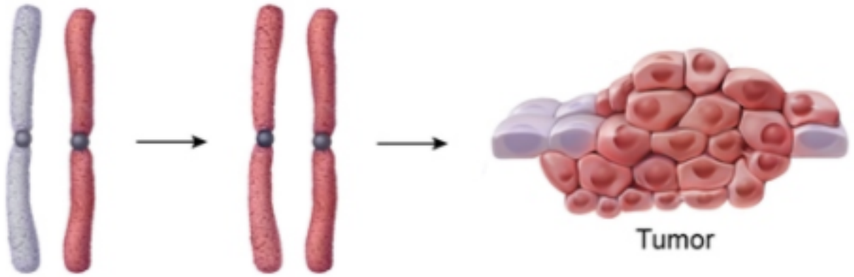

©UWorld

Zoom In Zoom Out Reset Add To Flash Card

Settings

1
2
3
4
5
6
7
8
9
10
11

Item 11 of 11
Question Id: 18929

Mark | Previous | Next | Full Screen | Tutorial | Lab Values | Notes | Calculator | Reverse Color | Text Zoom | Settings

A 64-year-old man develops diarrhea, abdominal pain, nausea, vomiting, and anorexia 3 weeks after starting radiation therapy for prostate cancer. Physical examination shows abdominal tenderness. Sigmoidoscopy reveals hyperemia, edema, erosion, and ulceration of the intestinal mucosa. Stool and serum chemistries are normal. Radiation enteritis is suspected. Which of the following is most likely the primary mechanism responsible for this patient's intestinal changes?

A. Generation of reactive oxygen species

B. Increased activity of the ubiquitin-proteasome system

C. Inhibition of DNA polymerase

D. Inhibition of thymidylate synthesis

E. Prevention of microtubule assembly

Submit

Block Time Remaining: 00:00:21
TUTOR

0 | Feedback | Suspend | End Block

A 64-year-old man develops diarrhea, abdominal pain, nausea, vomiting, and anorexia 3 weeks after starting radiation therapy for prostate cancer. Physical examination shows abdominal tenderness. Sigmoidoscopy reveals hyperemia, edema, erosion, and ulceration of the intestinal mucosa. Stool and serum chemistries are normal. Radiation enteritis is suspected. Which of the following is most likely the primary mechanism responsible for this patient's intestinal changes?

- ✓ A. Generation of reactive oxygen species (69%)
- B. Increased activity of the ubiquitin-proteasome system (10%)
- C. Inhibition of DNA polymerase (8%)
- D. Inhibition of thymidylate synthesis (7%)
- E. Prevention of microtubule assembly (4%)

Omitted
Correct answer
A

69%
Answered correctly

01 sec
Time Spent

06/19/2020
Last Updated

Explanation

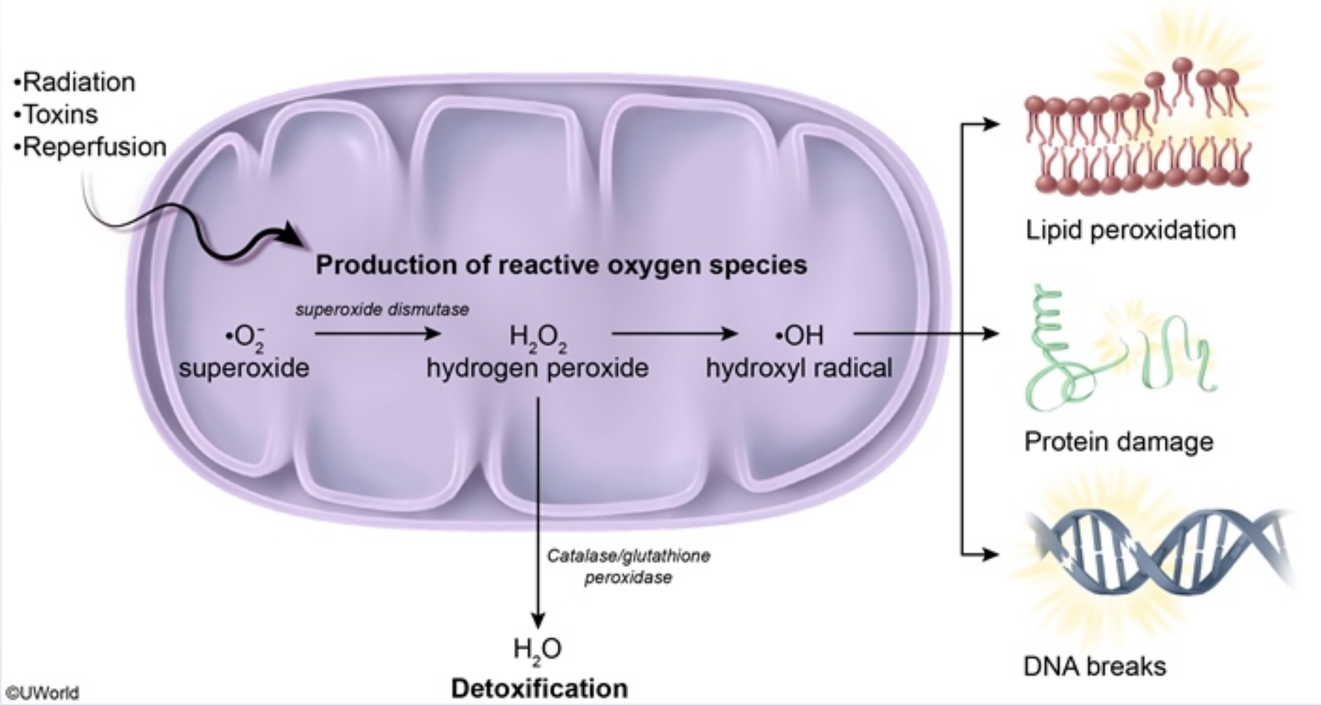

This patient developed signs of **acute radiation enteritis** (eg, abdominal pain, diarrhea, inflammation and denudation of intestinal mucosa) 3 weeks after starting radiotherapy for **prostate cancer**. Therapeutic **ionizing radiation** is commonly used to treat or palliate many types of cancer (eg, prostate, breast) and causes cell damage through 2 primary mechanisms:

- DNA double-strand breakage: Breakage of both strands is required; single-strand breaks can be repaired by polymerases.
- **Generation of reactive oxygen species**: Unstable molecules formed by the ionization of water; oxygen free radicals can cause cellular and DNA damage.

Radiation-induced DNA damage impairs mitosis and initiates **apoptosis** of susceptible cells, including **intestinal crypt stem cells** and other highly proliferative cells (eg, cancer cells, hematogenous precursors). Cellular damage also induces an immune response characterized by

- **Generation of reactive oxygen species**: Unstable molecules formed by the ionization of water; oxygen free radicals can cause cellular and DNA damage.

Radiation-induced DNA damage impairs mitosis and initiates **apoptosis** of susceptible cells, including **intestinal crypt stem cells** and other highly proliferative cells (eg, cancer cells, hematogenous precursors). Cellular damage also induces an immune response characterized by increased expression of **proinflammatory cytokines** (eg, IL-1, IL-6, tumor necrosis factor-alpha) and migration of leukocytes (eg, neutrophils) to the affected tissue, processes that produce additional reactive oxygen species and contribute to the radiation-induced tissue damage.

In the gastrointestinal tract, these changes result in progressive inflammation, edema, and **mucosal denudation** that decrease the absorptive area. Abdominal pain and diarrhea typically manifest several weeks after radiotherapy is started. In some cases, the effects of radiation exposure can be delayed until years after radiation exposure and present as complications of intestinal fibrosis (eg, strictures, adhesions, bowel obstruction).

(Choice B) The ubiquitin-proteasome system has an integral role in maintaining normal cell function by degrading damaged proteins and contributing to cell cycle control. Although proteasome activity normally increases in response to oxidative stress, this system is inhibited by ionizing radiation, potentiating the apoptotic effects of radiotherapy.

(Choices C, D, and E) Many chemotherapeutic agents impair essential steps in the DNA and cellular repair processes and can potentiate the effects of ionizing radiation. Although inhibition of DNA polymerase (eg, nucleoside analogues), inhibition of thymidylate synthesis (eg, 5-fluorouracil), and prevention of microtubule assembly (eg, vinblastine) would contribute to the cytotoxic effects of radiation, radiation-induced tissue damage occurs primarily through the generation of free radicals.

Educational objective:
Ionizing radiation causes cellular and DNA damage primarily through generation of reactive oxygen species, which can trigger progressive inflammation and tissue damage. In the gastrointestinal tract, the acute effects of radiation exposure typically occur several weeks after radiotherapy is initiated and manifest as abdominal pain and diarrhea due to mucosal denudation, inflammation, and edema.

References

- Mechanisms of radiation-induced normal tissue toxicity and implications for future clinical trials